
UNDER THE RADAR: NEUROIMAGING EVIDENCE IN THE CRIMINAL COURTROOM

Lyn M. Gaudet & Gary E. Marchant***

ABSTRACT

This Article analyzes court decisions in 361 criminal cases involving neuroimaging evidence through the end of 2015. There has been a steady upward trend in the number of criminal cases considering neuroimaging evidence with the number of reported decisions being the highest in the most recent period of 2013–2015. Neuroimaging evidence has been used in competency, guilt, and penalty phases of criminal trials, with the most efficacy being seen in the penalty phase, especially in capital cases. In order to provide a helpful analysis of uses and trends of this specific type of evidence, this Article includes an identification of the specific neuroimaging modality used or requested in each case (CT, MRI, EEG, PET, SPECT), the reason for the request for neuroimaging, the legal argument involving the imaging data, and the court’s response. In addition, common concerns regarding the use of neuroimaging data are also addressed, including the complexity of the various techniques and analysis, individual variability of the brain, the time gap between scanning and the criminal act, and the ability to make statements about groups versus about one individual. As supported by the trends demonstrated in this analysis, there has been a shift in recent years from discussion about whether neuroimaging evidence is relevant and admissible toward admissibility of this type of evidence and a focus on the substantive results and appropriate use of the neuroimaging data.

TABLE OF CONTENTS

I. Introduction	578
II. Background on Neuroimaging	583
A. Neuroimaging Technologies	583
B. Courtroom Techniques	587
III. Study Methodology	593

* Lyn M. Gaudet is the Director of MINDSET consulting group and a current Research Fellow and the former Research Director of the Center for Law, Science & Innovation at Sandra Day O’Connor College of Law, Arizona State University (ASU).

** Gary E. Marchant is a Regents’ Professor and Lincoln Professor of Emerging Technologies, Law and Ethics, as well as the Faculty Director of the Center for Law, Science & Innovation at Sandra Day O’Connor College of Law, ASU. The Authors appreciate the helpful research assistance of Katherine Hanna and Austin Miller.

IV. Neuroimaging Evidence in Criminal Cases: Findings.....	596
A. Guilt.....	597
1. Element of Crime Cases.....	597
a. Defendant's neuroimaging evidence admitted.....	598
b. Defendant's neuroimaging evidence not admissible.....	603
c. Prosecution's reliance on neuroimaging evidence.....	612
2. Requests to Obtain a Brain Scan	614
3. Ineffective Assistance of Counsel	619
B. Penalty.....	623
1. Admissible but Ineffective Mitigating Evidence	627
2. Defendant Seeks Brain Scan as Mitigating Evidence	629
3. Admissibility of Brain Scan in Penalty Phase.....	635
4. Claims of Ineffective Assistance of Counsel in the Penalty Phase.....	638
C. Competence.....	647
V. Discussion	651
A. "New Chapter" in Death Penalty History	654
B. Fears and Concerns	655
C. The Future of Neuroimaging Evidence in the Courtroom	657
D. A Final Thought Experiment	660
VI. Conclusion	661

I. INTRODUCTION

Advances in neuroimaging have revolutionized how scientists seek to understand the elusive relationship between brain and behavior.¹ Over the past decade or so, the use of these same advancements in the courtroom has accelerated. We are now on the verge of a fundamental paradigm shift in which neuroimaging is becoming a highly significant part of the criminal justice process with the rapid advancement of forensic neuropsychiatry and

1. "Neuroimaging" is a subset of neuroscience evidence that involves scanning the brain using various techniques to evaluate the structural or functional characteristics of an individual's brain. E. Spencer Compton, Note, *Not Guilty by Reason of Neuroimaging: The Need for Cautionary Jury Instructions for Neuroscience Evidence in Criminal Trials*, 12 VAND. J. ENT. & TECH. L. 333, 339–40 (2010). These neuroimaging techniques are often referred to as "brain scanning," but we will use the term neuroimaging throughout this Article. The various neuroimaging modalities are summarized in Part II *infra*.

neuroscience. This emerging science and technology is raising many complex scientific, doctrinal, policy, and ethical questions with which the legal system is now grappling. This Article traces the evolution and application of neuroimaging evidence in U.S. criminal cases involving the use or attempted use of neuroimaging evidence in nine different contexts, spanning the guilt, sentencing, and competency phases of criminal trials.²

Like any disruptive emerging technology, the use of neuroimaging in the criminal courtroom has faced and will continue to face controversy and uncertainty, including claims that the attempted use of neuroimaging evidence is premature or inappropriate. Some commentators are skeptical of the value of neuroimaging in the courtroom and also wary of its potential for distortion or manipulation.³ Yet others are even more pessimistic, believing that neuroimaging evidence will have relevance in criminal court only in the most extreme circumstances, if at all, irrespective of the independent validity and reliability of the technology.⁴ On the other hand, proponents of the technology believe that its use can make criminal law more effective, fair, and accurate.⁵

The controversy is fueled by actual or anticipated cases in which neuroscience evidence is clearly misused or overly emphasized. Yet all commentators should be able to agree that it is not an appropriate or advisable strategy to use *only* evidence of a neuroimaging finding and not have other evidence to support the claim or defense at issue. Those unfortunate situations where the evidence is misused in this way, in the past or future, represent a shortcoming of the attorney and the experts they have hired—not of the technology itself.

When used appropriately, neuroimaging technologies simply offer a way to gather data regarding brain structure and function, which can be important data for mental health and medical professionals to consider as part of a comprehensive mental health evaluation—something that is routinely needed in a number of legal contexts, especially for defendants in

2. The three Appendices accompanying this Article cover 361 cases and are split according to the above-mentioned phases of criminal trials: Appendix A discusses the guilt phase, Appendix B covers the penalty phase, and Appendix C addresses the competency phase. The Appendices are available on the *Drake Law Review* website, <https://drakelawreview.org/vol-64-no-3-2016/>.

3. See *infra* Part II.B.

4. See *infra* Part II.B.

5. See *infra* Part II.B.

capital criminal proceedings. Such a characterization is entirely consistent with the American Bar Association's Guidelines for the Appointment and Performance of Defense Counsel in Death Penalty Cases, which encourage defense counsel to seek out whatever testing is needed to investigate thoroughly their clients' mental health and neurological statuses. The guidelines specifically state: "Diagnostic studies, neuropsychological testing, appropriate brain scans, blood tests or genetic studies, and consultation with additional mental health specialists may also be necessary."⁶

There are a number of broader debates about neuroscience and the law that discuss issues such as determinism and free will.⁷ While philosophically rich and intellectually interesting, it is important to point out that these remain largely academic debates. Practicing attorneys are not having these debates amongst themselves but rather are focusing on whether any technique or tool—neuroimaging included—has the potential to help their clients or can be excluded through admissibility challenges or rebutted through effective cross-examination.⁸ There is a significant disconnect between how neuroscience evidence is perceived and presented in actual courtrooms and what scholars seem to think are critical issues. In criminal litigation, defendants and their counsel will use whatever tools are available to them while prosecutors will be skeptical and critique the tools used by the

6. See ABA, GUIDELINES FOR THE APPOINTMENT AND PERFORMANCE OF DEFENSE COUNSEL IN DEATH PENALTY CASES 31 (rev. ed. 2003), http://www.americanbar.org/content/dam/aba/migrated/2011_build/death_penalty_representation/2003guidelines.authcheckdam.pdf.

7. For instance, those who are anxiously awaiting the "neurolaw" revolution also anticipate reformation of what is essentially a retributivist justice system. See, e.g., Joshua Greene & Jonathan Cohen, *For the Law, Neuroscience Changes Nothing and Everything*, 359 PHIL. TRANSACTIONS ROYAL SOC'Y B: BIOLOGICAL SCI. 1775, 1775–84 (2004); see also Jeffery Rosen, *The Brain on the Stand*, N.Y. TIMES (Mar. 11, 2007), http://www.nytimes.com/2007/03/11/magazine/11Neurolaw.t.html?_r=1. Others believe that the criminal justice system only requires the sustainability of folk psychology, which is the human's capacity to attribute explanation and predict behavior, and any techniques, including neuroscience, that may be used to undermine one's free will, are merely a distraction that are ultimately irrelevant to questions of competency, guilt, or punishment. See, e.g., Stephen J. Morse, *New Neuroscience, Old Problems*, in NEUROSCIENCE AND THE LAW: BRAIN, MIND, AND THE SCALES OF JUSTICE 157 *passim* (Brent Garland ed., 2004); Stephen J. Morse, *The Non-Problem of Free Will in Forensic Psychiatry and Forensic Psychology*, 25 BEHAV. SCI. & L. 203, 210–12 (2007) [hereinafter Morse, *The Non-Problem*].

8. While neuroscience evidence could conceivably be used by both defense counsel and prosecutors in criminal cases, to date neuroscience evidence has been affirmatively introduced primarily by the defense. See Rosen, *supra* note 7.

defense.⁹ These are their respective and appropriate roles—and the use of neuroimaging evidence in the criminal courtroom needs to be assessed through that prism to understand existing practices and future trends.

While debates about the potential role of brain scanning and its purported value continue unabated, the practical reality is that brain scan technology *is* being used in the criminal courtroom, perhaps much more frequently than many observers appreciate. Famous cases such as *United States v. Hinckley*¹⁰ capture the media's attention, but it is the crime and the criminal that captivate popular attention, not the substantive evidence presented at trial.¹¹ Most cases in which neuroimaging evidence has been admitted are routine state murder cases, often receiving little or no media attention.¹² It is only in the past decade that neuroimaging has reached widespread use among relevant scientific communities, resulting in a wave of peer-reviewed scientific studies as well as higher-profile articles in the popular and trade press.¹³ The growing body of research and the attention neuroimaging has garnered have encouraged defense counsel across the country to utilize such evidence, forcing trial judges to conduct some degree of *Frye* and *Daubert*¹⁴ analyses in consideration of its admissibility.¹⁵ This trend is reflected by the increasing frequency of discussion of neuroimaging

9. *See id.*

10. *United States v. Hinckley*, 525 F. Supp. 1342 (D.D.C. 1981), *clarified on denial of reconsideration*, 529 F. Supp. 520 (D.D.C.), *aff'd*, 672 F.2d 115 (D.C. Cir. 1982), *abrogated by* *Hudson v. Palmer*, 468 U.S. 517 (1984); *see also* Univ. of Mo. Kan. City, *The Trial of John W. Hinckley, Jr.*, TRIAL ACCT., <http://law2.umkc.edu/faculty/projects/ftrials/hinckley/ACCOUNT.HTM> (summarizing the Hinckley trial and stating trial court reversed “initial court ruling to exclude [CAT scan] evidence, [after] prosecution waived its objection and allowed [defense to use] slide projectors to show [Hinckley’s] CAT-scan[s] to the jury”; everyone agreed Hinckley had wider than normal sulci, “spaces between the skull and brain,” but disagreed as to its significance; one defense expert believed the sulci was critical to Hinckley’s diagnosis of schizophrenia).

11. *See This Day in History: Hinckley Not Guilty by Reason of Insanity*, HISTORY.COM, <http://www.history.com/this-day-in-history/hinckley-not-guilty-by-reason-of-insanity> (last visited June 18, 2016).

12. *See* cases cited in Appendices A, B, & C, *supra* note 2.

13. *See* Deborah Denno, *The Myth of the Double-Edged Sword: An Empirical Study of Neuroscience Evidence in Criminal Cases*, 56 B.C. L. REV. 493, 495–98 (2015).

14. *See infra* Part IV.A.1.b.

15. *See* Jane Campbell Moriarty, *Flickering Admissibility: Neuroimaging Evidence in the U.S. Courts*, 26 BEHAV. SCI. & L. 29, 38–40 (2008) (summarizing cases addressing neuroimaging and its admissibility under variations of the *Frye* and *Daubert* standards).

evidence in reported appellate opinions as well as the frequent requests made for neuroimaging evaluations for capital criminal defendants that have yet to go to trial.¹⁶ Such requests, made by defense attorneys, are most often placed under seal to protect the constitutional rights of their clients and are not accessible to the public, including legal scholars.¹⁷

As the underlying science continues to grow and evolve, so does the judiciary's evaluations and rulings on this type of evidence. In a few jurisdictions, certain types of neuroimaging evidence have not been admitted to date, yet the same techniques and similar evidence have been admitted elsewhere.¹⁸ In some instances, judges have accused attorneys of using requests for neuroimaging as a stall tactic or fishing expedition—a judicial admonishment that is certainly not unique to neuroimaging evidence.¹⁹ However, the statistics are clear that the trend is toward the incorporation of neuroimaging evidence.²⁰ Furthermore, the field is advancing so rapidly that it cannot be taken for granted that technology inadmissible today for a certain purpose will not be admissible in its advanced form, or for a different purpose, tomorrow.

Professor Deborah Denno has cautioned (appropriately in our view) that discussion of the use of neuroscience evidence must be “grounded in fact rather than hyperbole.”²¹ This Article seeks to add to the fact-based discussion and empirical analysis of neuroscience evidence in the criminal courtroom. This Article provides an account of different types of neuroimaging evidence proffered in the competency, guilt, and penalty phases of criminal adjudication. By examining the context and reasons for requesting, admitting, and denying neuroimaging evidence in past criminal cases, this Article contributes to the empirical record of how the courts have

16. See, e.g., Nita A. Farahany, *Neuroscience and Behavioral Genetics in US Criminal Law: An Empirical Analysis*, 2 J.L. & BIOSCIENCES 485, 486 (2015); Denno, *supra* note 13, at 500–02. See generally Moriarty, *supra* note 15 (reviewing the admissibility of neuroimaging evidence in U.S. courts to date and identifying trends in court decisions about such evidence).

17. See Amanda C. Pustilnik, *Neurotechnologies at the Intersection of Criminal Procedure and Constitutional Law*, in THE CONSTITUTION AND THE FUTURE OF THE CRIMINAL JUSTICE IN AMERICA 109, 144–47 (John T. Parry & L. Song Richardson eds., 2013) (discussing the implications of neuroimaging as it relates to the Fourth and Fifth Amendments), http://papers.ssrn.com/sol3/papers.cfm?abstract_id=2143187.

18. See Moriarty, *supra* note 15, at 42–44.

19. See, e.g., *United States v. Phillips*, No. 89-5686, 1990 WL 92625, at *2 (6th Cir. July 3, 1990) (per curiam).

20. See Farahany, *supra* note 16.

21. Denno, *supra* note 13, at 494.

actually responded to neuroimaging evidence.

In Part II, we briefly describe the available neuroimaging technologies and their applications, identifying and addressing some of the issues and controversies concerning their use in courtrooms. Part III describes the methodology of our study and relevant caveats and limitations of our approach. Part IV is the main body of the paper and presents our findings from the available case law. This Part is divided into three major sections that correspond to the three principal applications of neuroimaging evidence: mitigation, guilt, and competency. Finally, in Part V, we provide some discussion and conclusions flowing from our results.

II. BACKGROUND ON NEUROIMAGING

A. Neuroimaging Technologies

Neuroimaging involves the application of one or more of a variety of technologies that are able to measure and map brain parameters and to use the results to differentiate brain regions with respect to the measured parameters for purposes of describing, analyzing, or comparing brains.²² The imaging technologies that appear in the cases in this study are abbreviated as an alphabetical soup of MRI, fMRI, CAT, PET, SPECT, EEG, and BEAM analysis. These modalities can be divided into two categories: structural and functional.²³ Structural techniques capture the physical structure of the brain, whereas functional brain scans measure various changes in the brain (e.g., electrical activity, blood flow, etc.) that are believed to correlate to brain processes.²⁴ A very brief lay explanation of the technology underlying the various scanning technologies is provided below, beginning with structural scanning technologies followed by the functional methods.

Both magnetic resonance imaging (MRI) and computed axial tomography (CAT) scans produce structural images of the brain, analogous to the image rendered by an X-ray.²⁵ A CAT scan uses a number of two-dimensional X-rays to create a three-dimensional image of the brain.²⁶ MRI

22. See Moriarty, *supra* note 15, at 30–32.

23. See Denno, *supra* note 13, at 500 n.35.

24. See Moriarty, *supra* note 15, at 30–32; see also Denno, *supra* note 13, at 500 n.35.

25. Moriarty, *supra* note 15, at 31.

26. *Id.*

uses magnetic fields to create a representation of the brain structure.²⁷ It is generally recognized that MRI produces a better image than CAT scans because there is a greater contrast between soft tissues, including gray and white matter, which results in a clearer image of brain structures.²⁸ While it is generally accepted that MRI and CAT scans produce accurate representations of the brain structure, it is the interpretation of and conclusions drawn from the resulting images that can create controversy—with interpretation occurring through the vehicle of expert testimony in the criminal law context.²⁹ One of the issues in medical imaging and neuroradiology is that there is such variation in “normal” brain structure that it can sometimes be difficult to distinguish what is normal from what is abnormal.³⁰ In forensic contexts, one way to address this normative issue is through large comparative data sets.³¹ This is an area where there has been, and continues to be, a great deal of scientific progress in recent years. Indeed, there is already a sizeable literature that documents the application of advanced analytical techniques to populations with a variety of psychiatric, medical, and developmental conditions.³² Large scale data sets from patients with neurological and neuropsychiatric symptoms—as well as healthy controls—continue to grow. There will still likely be open questions regarding the interpretation of those findings, but there will be increasing amounts of comparative data that can inform expert opinions of imaging data.

There are other techniques that have been used in criminal trials that measure elements of brain function. Functional neuroimaging techniques are useful because many types of brain injuries do not affect the structure of brain tissue but can impair its ability to function properly, and those injuries would not be captured by a structural brain scan.³³ The oldest technology,

27. *Id.*

28. *Id.*; see also Peter Pressman, *Indications and Risks of a CT Scan Versus an MRI: Is a CT Scan or MRI Best for Me?*, VERYWELL, <https://www.verywell.com/mri-or-ct-scan-2488814> (last updated Jan. 29, 2016).

29. See Moriarty, *supra* note 15, at 31.

30. *Id.*

31. See, e.g., Catriona D. Good et al., *A Voxel-Based Morphometric Study of Ageing in 465 Normal Adult Human Brains*, NEUROIMAGE, July 2001, at 21 *passim*.

32. Voxel-based morphometry (VBM) is one such widely used technique. “[VBM] is a whole-brain, unbiased technique for characterizing regional cerebral volume and tissue concentration differences in structural magnetic resonance images.” *Id.* at 21.

33. See *Rogers v. State*, 783 So. 2d 980, 997–98 (Fla. 2001) (per curiam) (“Many forms of injury to the brain tissue both traumatic and otherwise, do not affect the

electroencephalography (EEG), measures electrical activity in the brain and produces a series of waveforms rather than a visual image of the brain.³⁴ A brain electrical activity mapping (BEAM) analysis is simply another way to present the data collected from an EEG; it transforms the data collected from an EEG into a colored, graphic display, rendering a more visually accessible output.³⁵ Quantitative methods that compare an individual subject's data to the data of hundreds of control subjects can be applied to EEG data as well. That method is called quantitative EEG or QEEG.³⁶

Both positron emission tomography (PET) and single photon emission computed tomography (SPECT) are functional neuroimaging techniques that measure levels of metabolic activity in the brain.³⁷ In both PET and SPECT scans, "organic compounds . . . are injected into the bloodstream and then tracked as they are metabolized in the brain tissue."³⁸ The data from both types of scans are sent to a computer that "creates visual images of the working brain."³⁹ PET produces better visual representations, but SPECT uses compounds that take longer to metabolize, thus resulting in more data.⁴⁰

The last technique that warrants mention is functional magnetic resonance imaging (fMRI). A technique discovered in the early 1990s, fMRI measures changes in blood oxygenation in the brain.⁴¹ The magnetic field reveals the relative oxygenation of the areas in the brain, and that data is used to create maps that identify which areas of the brain are being recruited

structural integrity of the brain tissue. Rather, the shape of the brain tissue remains unchanged, but the ability to function properly is altered by the injury.").

34. See Moriarty, *supra* note 15, at 31.

35. State v. Zimmerman, 802 P.2d 1024, 1026, 1028 (Ariz. Ct. App. 1990). To clarify, a BEAM analysis is not its own neuroimaging test, although the way it is discussed in some of the opinions (and consequently in this Article) can be misleading. If a defendant or expert requests a BEAM analysis, he or she is actually requesting an EEG, and the BEAM analysis is simply the way the data collected from the EEG is presented. See *id.* at 1026.

36. David S. Cantor, *An Overview of Quantitative EEG and Its Applications to Neurofeedback*, in INTRODUCTION TO QUANTITATIVE EEG AND NEUROFEEDBACK 3, 4 (James R. Evans & Andrew Abarbanel eds., 1999).

37. See Rogers, 783 So. 2d at 997; Moriarty, *supra* note 15, at 31.

38. Moriarty, *supra* note 15, at 31.

39. *Id.*

40. *Id.* at 32.

41. Kenneth K. Kwong et al., *Dynamic Magnetic Resonance Imaging of Human Brain Activity During Primary Sensory Stimulation*, 89 PROC. NAT'L ACAD. SCI. U.S. 5675, 5675 (1992).

at a given time or during a given mental task.⁴² From the maps, inferences about brain processes can be made.⁴³ The technique is extremely complex and involves a great deal of technical and statistical processes.⁴⁴ Despite its complexity and limitations, the technique is deepening science's understanding of brain processes and is on the current cutting-edge of neuroscience research.⁴⁵ It is worth noting that fMRI is by far the least frequently proffered neuroimaging technique in criminal cases to date, yet neuroscience and law commentators frequently mention it as an example of a technique that raises numerous methodological challenges for the law.⁴⁶ While fMRI is an advanced technique and learning how to collect, process, and analyze fMRI data properly requires years of advanced graduate and often post-graduate degree training, it is no different from other types of

42. *Id.* One area that has received a great deal of attention in the popular media is fMRI lie detection. Two companies, NoLieMRI and Cephos—both now defunct—aggressively marketed the service of fMRI lie detection to participants in the criminal justice system. In the 2010 case of *United States v. Semrau*, the federal court excluded Cephos's fMRI lie detection evidence proffered by the defense because it did not pass the *Daubert* standard. *United States v. Semrau*, No. 07-10074 MI/P, 2010 WL 6845092, at *3, *14 (W.D. Tenn. June 1, 2010); see also Alexis Madrigal, *Brain Scan Lie-Detection Deemed Far from Ready for Courtroom*, WIRED (June 1, 2010), <http://www.wired.com/wiredscience/2010/06/fmri-lie-detection-in-court>. In addition to some significant methodological issues with the fMRI lie detection studies performed to date, it was not known how well it worked in “real-world” settings. *Semrau*, 2010 WL 6845092, at *12 (citation omitted).

43. See *Semrau*, 2010 WL 6845092, at *3–4 (comparing brain activity reflected in an fMRI during different kinds of tasks to determine which areas of the brain are activated by deception).

44. See *id.*; Madrigal, *supra* note 42.

45. See Neal Feigenson, *Brain Imaging and Courtroom Evidence: On the Admissibility and Persuasiveness of fMRI*, 2 INT'L J.L. CONTEXT 233, 234 (2006). For a discussion of fMRI related to the legal system, see generally *id.* (analyzing the likely admissibility and probative value of fMRI images as evidence in American courts).

46. See Owen D. Jones et al., *Brain Imaging for Judges: An Introduction to Law and Neuroscience*, 50 CT. REV. 44, 44–45 (2014). For a brief summary of the very few lawsuits that have involved fMRI data or research, see Lyn M. Gaudet et al., *Functional Magnetic Resonance Imaging in Court*, 5 AM. J. BIOETHICS NEUROSCIENCE 43 *passim* (2014) [hereinafter Gaudet, Lushing & Kiehl]. An example of fMRI evidence presented in a criminal case is Partial Report of Proceedings at 23–48, *Illinois v. Dugan*, No. 05-CF-3491 (Ill. Cir. Ct. Nov. 5, 2009) (allowing neuroscientist to serve as an expert witness and present fMRI data of defendant as well as fMRI data of hundreds of individuals with psychopathy at defendant's sentencing hearing). For a brief summary of *Illinois v. Dugan*, see Gaudet, Lushing & Kiehl, *supra*, at 46.

evidence when proffered in a legal case.⁴⁷ In determining admissibility, the law should evaluate the underlying scientific rigor of the methods used to obtain, analyze, and interpret the data in question; the data's applicability to the legal issue at hand; and the scope of the corresponding expert's testimony.⁴⁸

Each type of brain scan has a certain purpose: MRI is the most sensitive technique to reveal brain injuries, tumors, and abnormalities; CAT scans are helpful for the identification of lesions, atrophy, and hemorrhages; EEG is useful in the detection of drug effects, epilepsy, and seizure disorders; and PET and SPECT measure the level of metabolic activity and blood flow in various regions of the brain, which leads to inferences about brain function and location of brain injuries.⁴⁹

B. Courtroom Techniques

Over the past three decades, the use of neuroimaging in clinical settings has become increasingly widespread, particularly as the links between neuroimaging results and psychiatric disorders have become more developed.⁵⁰ Notwithstanding the growing reliance on and applications of neuroimaging in the scientific and medical contexts,⁵¹ the use of such technologies in the courtroom is often sensationalized. For example, in the highly publicized and well-known case of *United States v. Gigante* in the late 1990s, the defendant, the alleged head of a mafia crime family, argued he was incompetent to stand trial as a result of organic brain damage due to either Alzheimer's disease or multi-infarct dementia.⁵² To support his claim, he attempted to rely on PET scan evidence.⁵³ The court determined that the

47. See Feigenson, *supra* note 45, at 235–36.

48. See Gaudet, Lushing & Kiehl, *supra* note 46 (discussing fMRI evidence in relation to *Daubert* and *Frye*, and stressing that fMRI evidence must be considered on a case-by-case basis).

49. See Moriarty, *supra* note 15, at 31.

50. See Joachim Witzel et al., *Neurophilosophical Perspectives of Neuroimaging in Forensic Psychiatry—Giving Way to a Paradigm Shift?*, 26 BEHAV. SCI. & L. 113, 115 (2008).

51. See, e.g., Christos Pantelis et al., *Structural Brain Imaging Evidence for Multiple Pathological Processes at Different Stages of Brain Development in Schizophrenia*, 31 SCHIZOPHRENIA BULL. 672, 684 (2005) (stating there are a “growing number of cross-sectional studies examining the presence and extent of brain structural abnormalities”).

52. *United States v. Gigante*, 982 F. Supp. 140, 145–47 (E.D.N.Y. 1997), *aff'd*, 166 F.3d 75 (2d Cir. 1999).

53. *Id.* at 147.

PET scan testimony was “dubious, based upon speculative scientific theories lacking full development, research, and support.”⁵⁴ Shortcomings of the evidence cited by the court included: (1) the lack of similarity between defendant’s age and condition and those in the PET scan control group and (2) the lack of prior PET scans of the defendant to compare with current scans.⁵⁵ The court concluded that the PET scan evidence was unreliable and, furthermore, neither credible nor persuasive.⁵⁶ Read out of context, and as sensationalized by some popular accounts of the decision, it could seem as though the court reacted extremely negatively to the introduction of neuroimaging data. The first point is that it is not appropriate to generalize from PET scans to all neuroimaging data. The second point is that the court’s criticism was attributable not to the imaging technology itself per se, but rather to the way in which the proponent was attempting to misuse that particular technology in the case, specifically trying to diagnose the defendant with a disorder that did not make sense. This is a typical example of an instance where the shortcomings of the proffered neuroimaging evidence and testimony do not lie in the scan technology itself but with its application in a particular context. This then raises the obvious question of whether there are some applications of brain scan technology in criminal cases that are currently appropriate. As discussed below, courts have been very receptive to different types of neuroimaging evidence in other cases,⁵⁷ and those cases are easily distinguished from cases like *Gigante*. Further, the cases that often make the news are not necessarily representative of how certain evidence is presented and received.

Scholarly opinions on the use of brain scanning evidence in criminal law cases have focused on a few critical issues. Neuroimaging scans, particularly functional assays, measure certain properties of the brain and then represent those measurements in graphical reconstructions that show

54. *Id.*

55. *Id.* (stating the control group consisted of only a small group of people that were not selected at random, “its members grossly differed from defendant in age and background,” and “[n]one . . . were under the influence of drugs”).

56. *Id.* at 148 (stating further that defendant’s experts “were not consistent with other evidence in the case”).

57. See, e.g., *Roberts v. Norris*, 526 F. Supp. 2d 926, 927–29 (E.D. Ark. 2007) (detailing that “magnetic resonance imaging (MRI) revealed that the accident destroyed one-fifth of [defendant’s] right frontal lobe,” thereby inhibiting defendant’s power to exercise emotional control). Other examples of favorable reception to brain scanning evidence are provided in Part IV *infra*.

some regions of the brain are “lit up” (or active) while others are not.⁵⁸ Critics will point out that these “pictures” are not actual photographs of brain activity, but rather renderings or animations that are based on assumptions that determine the graphic representation.⁵⁹ These critics express concerns about the meaning and significance of these graphic representations, including the potential for an expert witness to manipulate the “set points” and other parameters to make the results more or less dramatic.⁶⁰ A related concern is that juries will give undue weight and significance to the patterns and “abnormalities” shown on a neuroimaging representation.⁶¹ This concern has prompted recommendations that safeguards, such as cautionary jury instructions or even exclusion, may be used to protect against the undue influence of the images.⁶²

Two points should be noted in response to those criticisms. The first is that an expert who is going to testify to any neuroimaging evidence should be able to provide the court with his or her exact methodology for obtaining and analyzing the images.⁶³ For example, the expert should be able to share the specific sequences used to collect the data and the software packages and statistical parameters used to analyze the evidence.⁶⁴ Also, both sides should have access to the exact data that was collected so opposing experts can

58. See Jones et al., *supra* note 46, at 48–50 (providing an introduction to brain imaging as it relates to the law).

59. Bridget Pratt, Article, “Soft” Science in the Courtroom?: The Effects of Admitting Neuroimaging Evidence into Legal Proceedings, PENN BIOETHICS J., Apr. 2, 2005, at 1, 3.

60. *Id.*

61. See Shelley Batts, *Brain Lesions and Their Implications in Criminal Responsibility*, 27 BEHAV. SCI. & L. 261, 261 (2009); Teneille Brown & Emily Murphy, *Through a Scanner Darkly: Functional Neuroimaging as Evidence of a Criminal Defendant’s Past Mental States*, 62 STAN. L. REV. 1119, 1119 (2010); Joseph Dumit, *Objective Brains, Prejudicial Images*, 12 SCI. CONTEXT 173, 183–84 (1999); Jessica R. Gurley & David K. Marcus, *The Effects of Neuroimaging and Brain Injury on Insanity Defenses*, 26 BEHAV. SCI. & L. 85, 86 (2008); Adina L. Roskies, *Are Neuroimages Like Photographs of the Brain?*, 74 PHIL. SCI. 860, 871 (2007); Adina L. Roskies, *Neuroimaging and Inferential Distance*, 1 NEUROETHICS 19, 20 (2008); Jennifer Kulynych, Note, *Psychiatric Neuroimaging Evidence: A High-tech Crystal Ball?*, 49 STAN. L. REV. 1249, 1259 (1997); Pratt, *supra* note 59, at 1.

62. Compton, *supra* note 1, at 347 (stating safeguards are necessary “[d]ue to the high probative value of neuroscience evidence”).

63. See *Daubert v. Merrell Dow Pharm., Inc.*, 509 U.S. 579, 592–93 (1993).

64. See FED. R. EVID. 705 (“[T]he expert may be required to disclose [the underlying] facts or data on cross-examination.”).

review and analyze the same data.⁶⁵ It is simply not accurate to portray forensic imaging as a black box where the expert's word must be taken for granted. Experts may also disagree as to whether the collected data was sufficient for the purposes of the examination, but such a disagreement is within the purview of subject matter experts in a given field and will most often speak to weight and not admissibility—and such disagreement among experts is not unique to neuroimaging.⁶⁶ In the event of questions about methodology of imaging data collection and analysis in any case, these issues can—and should—be raised and discussed by the respective attorneys and experts to the court's satisfaction.⁶⁷

The second point is that a 2011 study that surveyed the impact of neuroimaging evidence on over 1,400 potential jurors found no such prejudicial effects of neuroimages presented in the context of a mock criminal case.⁶⁸ This large-scale empirical study undermines these concerns and suggests that jurors would not be unduly influenced by neuroimages.⁶⁹

A second set of issues raised by commentators involves the variability of the brain. One dimension of this variability is the individuality of the brain, discussed briefly above.⁷⁰ Every person's brain is unique, and so it is difficult to draw any reliable conclusion from the observation that a particular individual's brain shows some type of distinctive or unusual pattern or characteristic.⁷¹ Especially given the plasticity of the brain, the claim is that it is difficult to draw conclusions about the significance and

65. See FED. R. CIV. P. 35(b)(4).

66. See *Daubert*, 509 U.S. at 595–97 (discussing Federal Rule of Evidence 702 as pro-admissibility and stating, “Vigorous cross-examination, presentation of contrary evidence, and careful instruction on the burden of proof are the traditional and approximate means of attacking shaky but admissible evidence.” (citation omitted)).

67. See *id.* at 594–95 (“The focus, of [Rule 702], must be solely on principles and methodology, not on the conclusions that they generate.”).

68. N.J. Schweitzer et al., *Neuroimages as Evidence in a Mens Rea Defense: No Impact*, 17 PSYCHOL., PUB. POL’Y, & L. 357, 357 (2011) (concluding that despite suggestive findings from previous research, a study of 1,476 jury-eligible participants revealed “no evidence that neuroimagery affected jurors’ judgments (verdicts, sentence recommendations, judgments of the defendant’s culpability) over and above verbal neuroscience-based testimony”).

69. *Id.* at 387–88 (summarizing the findings of the four experiments conducted in the study).

70. See *supra* notes 29–31 and accompanying text.

71. See *supra* notes 29–31 and accompanying text.

implications of the unique features of any one person's scan.⁷² One way to account for this individual variability in the analysis is to employ quantitative methods that compare an individual defendant's data to large data sets that can help define "normal" for purposes of allowing an expert to determine whether there are statistically significant findings in a defendant's scan.⁷³

Another dimension of the variability of brain scans is temporal. In criminal cases, the defendant's brain scan often is taken many years after the crime was committed, raising questions about the appropriateness of making extrapolations from these brain scans about the defendant's mental state at the time of the crime.⁷⁴ If the brain scan data are collected solely for the purpose of determining mental state at the time of the crime, then this is a reasonable criticism, but that is not usually the case. First, the majority of data collected are structural—not functional—data.⁷⁵ Therefore, they are not collected to speak to brain function at the time of the crime, but rather to assess structural compromise or gross anatomical findings.⁷⁶ If functional imaging data is collected, it is still most often collected to see if the data are consistent with injury or other disorders.⁷⁷ Another way to think of this issue is through the lens of state versus trait characteristics. States are transient—analogueous to our moods—whereas traits are more stable, like personality

72. See *supra* notes 29–31 and accompanying text.

73. See, e.g., Good et al., *supra* note 31, at 21. For example, quantitative MRI analysis is the comparison of the client's structural MRI data to a set of normative data. See Brown & Murphy, *supra* note 61, at 1138–39. Such quantitative analysis is helpful for two reasons. First, it can identify areas of injury or atrophy (many of which cannot be seen through traditional visual inspection of the data). Jones et al., *supra* note 46, at 46. Second, the normative data is what is required in order to make statistical based statements about the client's data being within or outside of normal limits. See Good et al., *supra* note 31, at 27.

74. E.g., Trapp v. Spencer, 479 F.3d 53, 63 (1st Cir. 2007), *abrogated by* Holland v. Florida, 560 U.S. 631, 649 (2010), *as recognized in* Holmes v. Spencer, No. 15-1216, 2016 WL 2610658, at *2 n.1 (1st Cir. May 6, 2016).

75. See Adam Teitcher, Note, *Weaving Functional Brain Imaging into the Tapestry of Evidence: A Case for Functional Neuroimaging in Federal Criminal Courts*, 80 FORDHAM L. REV. 355, 361–63 (2011).

76. Scott N. MacMillan & Michael S. Vaughn, *Weighing the Evidence: Neuroimaging Evidence of Brain Trauma or Disorder in Courts*, 46 CRIM. L. BULL. 495 (2010), 46 No. 3 Crim. Law Bulletin ART 5 ("Structural scans show the actual structure of the brain, allowing for abnormalities or physical damage to be identified.").

77. See *id.* ("Offenders often seek a PET scan because it shows functionality of the brain, and most disorders show up on functional tests rather than on structural ones," (citation omitted)).

types.⁷⁸ The imaging data is trying to capture information about the person's underlying neurobiological traits—the physical composition of the brain as well as how it performs under certain conditions.⁷⁹ If the law required assessments to happen contemporaneously with the crime, experts would not be able to perform insanity evaluations (which are based on interviews after the event, sometimes years afterwards, and collateral review of files, documents, videos, photographs, etc.). Yet, such evaluations are performed, and expert opinions are admitted, even though they require experts to use historical information and data obtained after the fact to opine as to a defendant's mental state at the exact time of the crime.⁸⁰

A third concern is the “gap” between abnormalities shown in the neuroimage and the legal concepts relating to the mental state that is at issue in a criminal trial, such as culpability or responsibility. Even if a brain scan shows a clear abnormality, it is unclear how that abnormality affected the defendant—for example, whether or to what extent the defendant experienced violent impulses or could voluntarily control those impulses.⁸¹ This is a significant issue. While it is correct that this is not something that can be addressed solely by neuroimaging, it can potentially be informed by neuroimaging.⁸² Clinical evaluation of a client is necessary to determine how a client's cognitive abilities or mental illness relates to the legal questions at hand. A common neuroradiologist refrain is that doctors “should treat people not scans.” There are very few disorders diagnosed through imaging data alone. Even with such rare disorders when imaging findings are highly indicative of a condition, the patient must still be evaluated to determine if he or she is experiencing symptoms, identify symptom severity, and formulate a treatment plan.⁸³ So clinical correlation of neuroimaging findings is always recommended, but the neuroimaging data can help play a role in identifying potential areas of underlying damage and compromise.

78. William F. Chaplin et al., *Conceptions of States and Traits: Dimensional Attributes with Ideals as Prototypes*, 54 J. PERSONALITY & SOC. PSYCHOL. 541, 548 (1988).

79. Witzel et al., *supra* note 50, at 116–20; *see also* Farahany, *supra* note 16, at 487–88 (discussing use of neurobiological data to increase understanding of “traits” in criminal defendants).

80. *See, e.g.*, *Ferguson v. State*, 789 So. 2d 306, 313–14 (Fla. 2001) (per curiam).

81. *See, e.g.*, Morse, *The Non-Problem*, *supra* note 7, at 208.

82. Farahany, *supra* note 16, at 500 (addressing use of neurobiological evidence as a tool to “bolster claims of mental illness” and meet the legal standard for insanity).

83. *See* Moriarty, *supra* note 15, at 42–44 (discussing the “disagreement among scientists about what inferences about behavior properly can be drawn from neuroimages” in the context of criminal trials).

III. STUDY METHODOLOGY

As neuroimaging increasingly penetrates the practice of criminal law—especially capital cases⁸⁴—it is important to understand what types of neuroimaging claims and arguments are being made in the courtroom; whether those claims are directed at determinations of competency, guilt, or sentencing; what types of neuroimaging evidence are being presented; and what are the outcomes of attempts to introduce neuroimaging evidence in criminal trials. This Article seeks to help answer those questions by providing a comprehensive analysis of the use of neuroimaging evidence in U.S. criminal cases.

While a number of previous studies have considered the empirical track record of neuroscience evidence in criminal cases using selected examples,⁸⁵ two other comprehensive empirical studies have been published on the use of neuroscience evidence in U.S. litigation.⁸⁶ Professor Deborah Denno recently published a survey of 553 criminal cases from the period between 1992 and 2012 that used neuroscience evidence.⁸⁷ She considered cases involving both neuroimaging evidence and other types of neurological assessments.⁸⁸ Some of her major findings were that neurological evidence was introduced primarily by defendants as mitigating evidence in the sentencing phase of trial,⁸⁹ that prosecutors rarely tried to introduce neuroscience evidence of the defendant's future dangerousness as an

84. MacMillan & Vaughn, *supra* note 76 (“Many of these are death penalty cases, where the defendant attempts to use neuroimaging as a mitigating factor to reduce the possibility of a death sentence to life without parole.”).

85. See, e.g., *id.* (examining the admission of neuroimaging evidence at trial by reviewing U.S. Supreme Court, federal court, and state court cases); Moriarty, *supra* note 15, at 29 (exploring trends regarding the admissibility of neuroimaging evidence in U.S. courts).

86. Denno, *supra* note 13; Farahany, *supra* note 16.

87. Denno, *supra* note 13, at 500–01. Denno also identified 247 cases that involved neuroscience evaluations of the victim only (and not the defendant), which were not included in her more in-depth analysis. *Id.* at 501.

88. *Id.* at 505. Of the 553 cases she examined involving neuroscience evaluations of the defendant, 350 cases (63.29 percent) involved neuroimaging techniques, while other types of neurological assessments were used in the other cases. *Id.* at 500, 505, 549 (including the following types of tests: WAIS-R, MMPI, Bender-Gestalt Test, Rorschach Inkblot Test, Halstead Reitan Battery, Wide Range Achievement Test, Trial Making Test, Wisconsin Card Sorting Test, General Adaptive Behavior Testing, and Test of Memory Malinger).

89. *Id.* at 503.

aggravating factor in sentencing,⁹⁰ and that most successful claims by defendants were related to the ineffective assistance of counsel in the initial trial.⁹¹ The second comprehensive empirical study was published by Professor Nita Farahany, who assayed 1,585 criminal cases involving neurobiological evidence that were decided in the period from 2005 to 2012.⁹² She considered all types of neuroscience and behavioral genetics evidence, of which neuroimaging cases represented only 15 percent of the total cases.⁹³ Some of her major findings were that the use of neurobiological evidence in criminal trials was increasing over time,⁹⁴ that mitigation represented the largest class of use of such evidence,⁹⁵ and that a surprising number of cases featured neurobiological evidence in pretrial proceedings to evaluate the competency of the defendant to stand trial.⁹⁶

The present study builds on and extends the findings of Professors Denno and Faharnay in significant ways. First, this study provides an updated analysis, including cases through 2015, whereas the previous studies included cases through 2012.⁹⁷ This analysis therefore extends previous analyses by three full years, a time period in which there was a substantial increase in reported criminal cases involving neuroimaging evidence.⁹⁸ Inclusion of more recent cases is an important addition, as the discussion of use of neuroscience evidence in appellate opinions is increasing,⁹⁹ and there have been some new and important developments in how counsel and courts have dealt with neuroimaging evidence in criminal cases in recent years.¹⁰⁰

90. *Id.* at 526.

91. *Id.* at 507.

92. Farahany, *supra* note 16.

93. *Id.* at 486, 494.

94. *Id.* at 491–92 graph 1.

95. *Id.* at 491.

96. *Id.* at 495–96 graph 6.

97. *See supra* notes 90, 95 and accompanying text.

98. *See infra* Part V, Figure 1.

99. *See infra* Part V, Figure 1.

100. *E.g.*, *Forrest v. Steele*, 764 F.3d 848, 854–55 (8th Cir. 2014); *People v. Bowman*, No. B242467, 2014 WL 718416, at *6–7 (Cal. Ct. App. Feb. 26, 2014). An example of a unique context for a request for neuroimaging data is a 2014 opinion discussing a 2010 case involving Michael Minor who was convicted of conspiracy to distribute and possession with intent to distribute cocaine. *United States v. Minor*, No. 09-391, 2014 WL 4230934, at *1 (E.D. La. Aug. 26, 2014). Minor had suffered a gunshot wound to the head a year before his arrest. *Id.* Minor had pled guilty to the charges. *Id.* On appeal he requested his sentence be vacated and that he be allowed to undergo MRI and EEG testing that would establish he suffered from a traumatic brain injury (TBI) in the

Second, the present study more narrowly focuses only on criminal cases involving neuroimaging evidence, excluding cases involving other types of brain-related evidence such as discussions of brain damage generally without mention of imaging specifically, or behavioral genetics evidence. While there are some important similarities and overlaps between these different types of data, which is the value of looking at these types of data together in the previous studies, there is also value in the present study's approach in focusing only on cases that specifically reference neuroimaging in some way, thus permitting more precise analysis of uses and trends of this specific type of evidence.

This study identified and analyzed reported criminal cases involving neuroimaging published through the end of 2015. Cases were identified using searches of the Westlaw database¹⁰¹ and then were analyzed to ensure they involved the use or attempted use of neuroimaging evidence of a defendant in a criminal case.¹⁰² Secondary materials on some cases were obtained through Google and other online searches. A total of 361 criminal cases were identified and analyzed. The cases were categorized into three groups depending on the primary use for which the neuroimaging evidence was intended in the trial: (1) guilt phase, 134 cases; (2) penalty or sentencing phase, 171 cases; or (3) competency, 56 cases. Many of these cases are discussed in the text or footnotes of this Article; while the complete list of cases (including case citations, the type of imaging the case references, the

parietal lobe. *Id.* at *2. He claimed that as a result of the TBI he suffered from diminished capacity and was not competent to make a guilty plea. *Id.* at *3. His claims were denied. *Id.* at *4. Lastly, even though neuroimaging data was not collected, *State v. Jerome A.* is an interesting example of a prosecution expert referencing neuroscience data. *State v. Jerome A.*, No. 30261-2014, 2015 WL 5236301, at *11 (N.Y. Sup. Ct. Sept. 8, 2015), *rev'd* by 27 N.Y.S.3d 150 (App. Div. 2016). In support of the state's petition for sex offender civil management pursuant to N.Y. Mental Hygiene Law, the state's expert relied on published evidence that brain scan evidence distinguished psychopathy from other conditions and that the defendant in this case suffered from psychopathy. *Id.* at *10. The state's petition was denied. *Id.* at *1. The court found the state's expert—a licensed psychologist—was not qualified in neuroscience and did not rely on brain scanning of the individual defendant at issue in this case. *Id.* at *11. Yet the court stated that the expert's "use of brain scan evidence to support her position was fascinating." *Id.*

101. The Westlaw search terms used to identify cases were: ((BRAIN /3 SCAN!) FMRI "POSITRON EMISSION TOPOGRAPHY" SPECT EEG MEG) & (CRIMINAL MURDER RAPE KIDNAPPING BURGLARY GUILTY SENTENCING MITIGATION).

102. This study therefore excludes cases that involved use of neuroimaging to evaluate the damage in a crime victim's brain.

argument made, and the outcome) is provided in Appendices A, B, and C (available online).¹⁰³

An important caveat about this methodology is that it contains an inherent bias in case selection. Cases that involve the defendant's introduction and reliance on neuroimaging evidence that were successful at or before the trial stage, either by a jury decision (acquittal) or by the defendant obtaining a favorable plea bargain, tend to be unreported decisions and thus cannot be detected in Westlaw searches, which primarily only include appellate decisions or summary judgment decisions by trial courts. Further, only a small number of criminal cases ever proceed to trial, as the vast majority of criminal cases are settled out of court. Consequently, many cases—in particular, cases where the defendant was partially or completely successful—may not be identified through our methodology and thus not represented in the sample. Most of the cases in this analysis are appellate decisions or post-conviction reviews of decisions. Given the asymmetrical right of appeal in criminal cases, the defendant lost at trial in all of the cases included in this study. Thus, the totality of evidence presented in the defendant's case was lacking in some way because the defendant did not prevail at the trial court level. Further exaggerating the bias of the sample, appellate courts are deferential to trial court decisions. Since it is almost always defendants who have sought to rely on neuroimaging evidence in criminal cases reported to date, this bias will tilt the results against the acceptance of neuroimaging evidence, although the extent of this tilt is not known.¹⁰⁴

IV. NEUROIMAGING EVIDENCE IN CRIMINAL CASES: FINDINGS

The findings for cases in which neuroimaging evidence was considered for purposes of adjudicating guilt, sentencing, and competency are summarized separately below. For each of the three phases of a criminal trial, several different contexts in which the evidence was offered, sought, or otherwise litigated are described. Detailed summaries of some of the most

103. See *supra* note 2.

104. There have been a number of reports in newspapers across the nation of criminal trials in which the defendant attempted to use neuroimaging evidence but for which reported decisions are not available. These cases are therefore not included in the analysis of this Article. See, e.g., Terry Vau Dell, *Inmate's Motions to Drop Charges Rejected by Judge*, CHICOER NEWS (July 4, 2007), <http://www.chicoer.com/20070704/inmates-motions-to-drop-charges-rejected-by-judge>; Tonya Amburgey, *Abuse Trial Put On Hold*, HAZARD HERALD, Feb. 4, 2009.

interesting cases are provided in text boxes throughout the paper, a few from each phase of the trial. Lastly, Appendices A, B, and C provide complete lists of, and details of, all the cases included in the analysis.¹⁰⁵

A. *Guilt*

Neuroimaging evidence has been and is being admitted in the guilt phase to support a number of arguments, primarily to rebut intent or to support an insanity, mental disease, or mental defect defense.¹⁰⁶

A total of 134 cases were identified in which neuroimaging evidence was at issue in the guilt phase. There are three general contexts in which such evidence comes into play: (1) cases in which a brain scan has been conducted and the defendant attempts to use the evidence to rebut an element of the crime (for example, mens rea or specific intent) or the prosecution argues the evidence supports conviction of the crime charged;¹⁰⁷ (2) cases in which no neuroimaging has been conducted but the defendant seeks funding for a scan;¹⁰⁸ and (3) cases in which the defendant on appeal argues that his trial attorney provided ineffective assistance of counsel by failing to obtain or appropriately utilize neuroimaging evidence in the guilt phase.¹⁰⁹ These three applications are discussed separately.

1. *Element of Crime Cases*

In 26 cases, the defendants sought to introduce neuroimaging evidence to refute—or requested neuroimaging data that they claimed would help them refute—one or more elements of the alleged crime. In 15 of these cases, the neuroimaging evidence was admitted for this purpose, while in 11 cases, the neuroimaging evidence was excluded.¹¹⁰ In some cases where the defendant sought to introduce neuroimaging evidence that allegedly showed some type of defect or abnormality, the prosecution sought to introduce

105. See *supra* note 2.

106. For a more in-depth look at neuroimaging evidence as it relates to the insanity defense, see generally Michael L. Perlin, “*His Brain Has Been Mismanaged with Great Skill*”: *How Will Jurors Respond to Neuroimaging Testimony in Insanity Defense Cases?*, 42 AKRON L. REV. 885, 887 (2009) (considering “the impact of neuroimaging evidence on juror decision making in insanity defense cases”). See generally Appendix A, *supra* note 2.

107. See *infra* Part IV.A.1.

108. See *infra* Part IV.A.2.

109. See *infra* Part IV.A.3.

110. See *infra* Parts IV.A.1.a–b.

neuroimaging evidence that showed no abnormality.¹¹¹ These three sub-categories of cases (defense evidence admitted, defense evidence not admitted, and prosecution's introduction of neuroimaging evidence) are summarized separately below.

a. Defendant's neuroimaging evidence admitted. In 15 reported cases, neuroimaging evidence introduced by a criminal defendant was admitted into evidence to try to negate an element of the crime at issue. Defendants sought to use this neuroimaging evidence to support a variety of defenses in the guilt stage, including defective memory,¹¹² lack of impulse control,¹¹³ inability to form intent (both general and specific),¹¹⁴ inability to premeditate crime,¹¹⁵ as well as insanity.¹¹⁶ The specific arguments in these cases vary

111. See *infra* Part IV.A.1.c.

112. E.g., *People v. Herrera*, No. B163516, 2003 WL 22962809, at *1, *4 n.3, *6 (Cal. Ct. App. Dec. 17, 2003) (arguing defendant's SPECT scans showed he suffered from temporal lobe damage causing "scattered" thinking and memory problems, and thus defendant did not intend to steal items from a grocery store but rather simply forgot to pay for them).

113. E.g., *People v. Musselwhite*, 954 P.2d 475, 482–83 (Cal. 1998) (arguing that defendant "suffered from organic brain damage"—revealed by a BEAM analysis—"which, compounded by extended crack cocaine abuse, prevented him from forming the mental state required for the commission of murder in the first degree"); *People v. Haney*, No. A110037, 2006 WL 3735949, at *2–3 (Cal. Ct. App. Dec. 20, 2006) (arguing scan demonstrated defendant's brain was "clearly dysfunctional and damaged" with "[s]ignificant decreased activity" in the frontal and temporal lobes, deficiencies that would affect his "judgment, impulse control, organization, planning, and empathy").

114. E.g., *Jackson v. Calderon*, 211 F.3d 1148, 1165 (9th Cir. 2000) (arguing that defendant's PET scan showed he was unable to form intent to kill because of chronic PCP abuse); *United States v. Erksine*, 588 F.2d 721, 722–23 (9th Cir. 1978) (arguing that "based upon objective evidence of mental defect shown by a brain scan" combined with observations about the defendant, the defendant did not have the specific intent necessary to be guilty of the crime charged: making a false statement with the purpose of influencing a federally insured bank); *Burgess v. State*, 827 So. 2d 134, 150 (Ala. Crim. App. 1998) (requesting court for funds to get MRI, which defendant pleaded would show lack of mental ability to form intent).

115. E.g., *People v. Steele*, 47 P.3d 225, 231–32 (Cal. 2002) (introducing abnormal BEAM analysis to argue against premeditation in murder case).

116. E.g., *Bryan v. Mullin*, 335 F.3d 1207, 1230–31 (10th Cir. 2003) (using SPECT scan evidence to support insanity claim); *United States v. Dilks*, No. 7:93-cr-00091, 2009 WL 528615, at *1 (W.D. Va. Feb. 27, 2009) (arguing that defendant's brain injury prevented him from forming the requisite intent to defraud the banks, from understanding the charges, and from contributing to his own defense), *aff'd* by *United States v. Modica*, 332 F. App'x 834 (4th Cir. 2009); *People v. Urdiales*, 871 N.E.2d 669, 698 (Ill. 2007) (offering MRI and SPECT scans as well as expert medical testimony to

based on the context, but the general pattern is that the defendant seeks to use neuroimaging evidence to demonstrate he suffers from some type of brain abnormality or damage that prevented him from being able to form the requisite intent or to control his actions.¹¹⁷ Accordingly, the defendant argues that he should be found not guilty, insane, or guilty of a lesser offense (e.g., second-degree murder or manslaughter).¹¹⁸ These cases could be placed into the category of “my brain damage or disorder makes me less—or not—responsible for the crime charged.”¹¹⁹

Of the 55 cases in which the defendant introduced, tried to introduce and then challenged the exclusion of neuroimaging evidence the defendant succeeded in five cases.¹²⁰ An example of this outcome is provided in Box 1.

support defendant’s claim of mental illness as well as reduced capacity).

117. See, e.g., *People v. Weinstein*, 591 N.Y.S.2d 715, 720 n.3, 722–23 (N.Y. Sup. Ct. 1992) (offering MRI, CAT, and PET scan evidence to show the presence of and metabolic imbalances caused by an arachnoid cyst and used to support the defense that, at the moment defendant allegedly killed his wife, “he lacked the cognitive ability to understand the nature and consequences of his conduct or that his conduct was wrong” and “that [his] cognitive power was impaired at that instant, in part, by organic brain damage”).

118. See *supra* notes 112–16 and accompanying text.

119. This is compared to the much rarer claim, “my brain damage or disorder made me do it.” For a story where this type of claim would arguably apply, see *Doctors Say Pedophile Lost Urge After Brain Tumor Removed*, USA TODAY (July 28, 2003), http://www.usatoday.com/news/health/2003-07-28-pedophile-tumor_x.htm.

120. *United States v. Sandoval-Mendoza*, 472 F.3d 645, 652–53, 656 (9th Cir. 2006) (overturning conviction for improper exclusion of medical expert testimony of a neuropsychologist and a neurologist regarding defendant’s brain tumor that they claimed impaired defendant’s intellect and judgment and made him susceptible to influence, and that was highly relevant to his defense against an entrapment charge); *United States v. Erskine*, 588 F.2d 721, 723 (9th Cir. 1978) (holding defendant was improperly denied opportunity to introduce evidence pertaining to the defense of lack of specific intent); *Roberts v. Norris*, 526 F. Supp. 2d 926, 927–28 (E.D. Ark. 2007) (granting defendant’s stay and abeyance motion because court was “impressed” by defendant’s serious brain injury; giving defendant an opportunity to present the claim that the brain injury prevented him from “competently waiving his right to appeal and seek state post-conviction relief”); *People v. Ford*, No. B1055848, 2005 WL 236487, at *7 (Cal. Ct. App. Jan. 25, 2005) (finding trial court’s exclusion of SPECT scan evidence was error but concluding the error was harmless because there was no reasonable probability that the jury’s verdict would have been different had the SPECT scan results been admitted); *People v. Jones*, 620 N.Y.S.2d 656, 657 (N.Y. App. Div. 1994) (finding trial court erred in denying defendant’s request for a brain scan because the defendant had a history of head trauma and possible permanent brain damage and that evidence would have been useful in his justification defense), *aff’d* by 654 N.E.2d 1209 (N.Y. 1995).

Box 1: *State v. Hinkle***Use of Brain Disorder to Disprove Guilt**

The Crime: On a June afternoon in 1993, Charles Hinkle got a ride to a local tavern after work in Paden City, West Virginia.¹²¹ At the tavern, he drank one-third of a can of beer and made a number of telephone calls, trying to locate someone who would give him a ride to his car.¹²² While at the tavern, Hinkle was not feeling well, complaining of dizziness and double vision.¹²³ Unable to locate anyone to drive him, the tavern owner's daughter agreed to give him a ride to his car.¹²⁴ Hinkle took an unopened can of beer with him.¹²⁵ At 7:30 that evening, after retrieving his car, Hinkle was driving northbound on Route 2.¹²⁶ Robert Barrett and his wife were traveling southbound on Route 2.¹²⁷ Hinkle's car gradually crossed the centerline, traveled straight for approximately 200 yards, and crashed head-on into the Barrett vehicle.¹²⁸ All individuals involved in the accident—Mr. Hinkle and Mr. and Mrs. Barrett—were seriously injured, and Mrs. Barrett ultimately died from her injuries.¹²⁹ Eyewitnesses to the crash said that while Mr. Barrett tried to avoid the crash by swerving and braking, Hinkle did not appear to make any effort to slow down, stop, or change the vehicle's direction.¹³⁰ Immediately after the accident, Hinkle was taken to the hospital, where his blood alcohol level was less than one thousandth of one percent.¹³¹ However, an MRI of Hinkle's brain to check for head injuries revealed an "undiagnosed brain disorder in the portion of his brain that regulates consciousness."¹³²

121. *State v. Hinkle*, 489 S.E.2d 257, 258 (W. Va. 1996).

122. *Id.*

123. *Id.*

124. *Id.*

125. *Id.*

126. *Id.* at 259.

127. *Id.*

128. *Id.*

129. *Id.*

130. *Id.*

131. *Id.*

132. *Id.*

The Neuroimaging Evidence: A medical doctor testified for the defense to the results of Hinkle's MRI.¹³³ The brain disorder was in the "reticular activating system of his brain," and it allegedly could have caused Hinkle to lose consciousness prior to the crash.¹³⁴ The doctor believed the disorder manifested itself between four and eight months before the accident.¹³⁵ In the doctor's opinion, Hinkle's memory loss the months before the crash could have been caused by the disorder, but his other complaints, including dizziness and blurred vision, were not symptoms of the disorder but more likely a result of Hinkle's chronic sinusitis.¹³⁶

The Trial: The jury was instructed that the defendant was not under the influence at the time of the accident and the defendant suffered from an organic brain disease or defect that affected the consciousness-regulating portion of his brain.¹³⁷ The jury was then charged that if one has an undiagnosed—as Hinkle's condition was—disease or defect, one "cannot be convicted of involuntary manslaughter," unless he knew or had reason to know that he had such a condition and that such a condition would impair his ability to drive to the extent he would endanger human life.¹³⁸ Despite the instruction's language, Hinkle was convicted of involuntary manslaughter.¹³⁹

The Appeal: On appeal, Hinkle argued he should be entitled to an insanity instruction; the court disagreed.¹⁴⁰ The issue on appeal was whether the jury had been adequately instructed on the defense of unconsciousness.¹⁴¹ The law on unconsciousness had been grossly underdeveloped in West Virginia, and the court had to reconcile these categories for this opinion.¹⁴²

133. *Id.* at 260.

134. *Id.*

135. *Id.*

136. *Id.*

137. *Id.* at 261 nn. 18–19.

138. *Id.* at 261.

139. *Id.*

140. *Id.* at 262 ("We agree partially with the State that technically the defense was one of unconsciousness as opposed to insanity.").

141. *Id.* at 264 ("The . . . questions are whether the evidence in the present case was sufficient to justify an unconsciousness instruction, and, if so, whether the instruction given by the court was adequate.").

142. *Id.* at 262–63.

Prior to this case, West Virginia law would have placed Hinkle's claim under insanity.¹⁴³ Here, the court explained that unconsciousness, or automatism, is separate and distinct from the insanity defense and is used to negate the voluntary act requirement and not rebut the mental elements of a crime.¹⁴⁴ Thus, the court decided unconsciousness belonged in the same category as the involuntary act of epilepsy, rather than the defense of insanity.¹⁴⁵ One of the reasons the court gave for this categorization was that periods of unconsciousness are often acute and temporary, while insanity tends to be a chronic condition.¹⁴⁶ Because of the different nature of the underlying conditions, a defendant that suffered unconsciousness would not likely require institutionalization, while a defendant who is legally insane frequently will.¹⁴⁷

The Result: The court reversed Hinkle's conviction.¹⁴⁸ A de novo review of the record is proper when there is a question as to whether a jury was correctly and sufficiently instructed.¹⁴⁹ The court disagreed with the language of the jury charge because there was practically "no evidence in the record to indicate that the defendant knew (or reasonably should have known)" that he had a brain disorder, "or that he knew (or reasonably should have known) that" his ability to drive a car was so impaired that he was endangering human life.¹⁵⁰ The court explained it was inclined to reverse the decision below for lack of sufficient evidence, which would prevent the State from retrying him.¹⁵¹ However, due to the court specifying exactly what the defendant's claim of unconsciousness entailed in the current opinion, the State did not have a full opportunity to respond to such a claim, so the court reversed due to the weight of the evidence with instructions for a retrial.¹⁵²

143. *See id.*

144. *Id.* at 263.

145. *Id.*

146. *Id.*

147. *Id.*

148. *Id.* at 266.

149. *Id.* at 262.

150. *Id.* at 264–66 (listing this lack of evidence issue as one of four considerations that led the court to reverse the defendant's conviction).

151. *Id.* at 266.

152. *Id.*

The Final Disposition: The State did not have any new evidence to present on retrial and consequently, the defense moved to dismiss the charges, consistent with the supreme court's opinion that the original evidence presented at trial was insufficient.¹⁵³ The trial judge denied the motion and set the case for retrial.¹⁵⁴ Neither the State nor the defense wished to endure a retrial and an agreement between defense counsel and the prosecution resulted in the prosecutor dismissing the manslaughter charges against Mr. Hinkle and issuing new charges against him for the misdemeanor of driving left of center.¹⁵⁵ That misdemeanor carries a maximum sentence of 10 days in jail.¹⁵⁶ Mr. Hinkle pled guilty to the misdemeanor, was sentenced to the 10 days in jail, and was ultimately given credit for time served.¹⁵⁷

b. Defendant's neuroimaging evidence not admissible. Over the last decade, a criminal defendant's attempt to introduce neuroimaging evidence to disprove guilt has been subject to numerous challenges under the standards for admissibility of scientific evidence with truly mixed results. Some courts have admitted this evidence, as documented in the previous subsection,¹⁵⁸ while others have excluded neuroimaging results and testimony. In 17 cases, the trial courts rejected the admissibility of neuroimaging evidence proffered by the defendant to try to disprove guilt, and the defendants challenged this exclusion on appeal.¹⁵⁹ When the evidence is excluded, the most frequent reason is that it lacked acceptance within the relevant scientific community, rendering it inadmissible under

153. Telephone Interview with John Butler III (July 26, 2011) (Mr. Butler was Mr. Hinkle's trial and appellate counsel).

154. *Id.*

155. *Id.*

156. *Id.*

157. *Id.*

158. *See supra* Part IV.A.1.a.

159. *E.g.*, *Bryan v. Mullin*, 335 F.3d 1207, 1217, 1218–23 (10th Cir. 2003); *United States v. Dilks*, No. 7:93-cr-00091, 2009 WL 528615, at *1–2 (W.D. Va. Feb. 27, 2009), *aff'd* by *United States v. Modica*, 332 F. App'x 834 (4th Cir. 2009); *Lard v. State*, 431 S.W.3d 249, 257 (Ark.), *cert. denied*, 135 S. Ct. 76 (2014); *People v. Pearson*, 297 P.3d 793, 835–37 (Cal. 2013); *People v. Ward*, No. B193719, 2008 WL 3906423, *5–9 (Cal. Ct. App. Aug. 26, 2008); *People v. Ford*, No. 1055848, 2005 WL 236487, at *7 (Cal. Ct. App. Jan. 25, 2005); *People v. Protsman*, 105 Cal. Rptr. 2d 819, 822–24 (Ct. App. 2001) (depublished).

either the *Daubert*¹⁶⁰ and *Frye*¹⁶¹ standards for admissibility of scientific evidence.¹⁶² Neuroimaging results do not speak for themselves; they must be

160. *Daubert v. Merrell Dow Pharm., Inc.*, 509 U.S. 579, 592–97 (1993). *Daubert* expanded judges' responsibilities by requiring them to take a more active gatekeeping role in assessing evidence and determining whether the evidence satisfies the requisite criteria before it is admitted in court. *Id.* at 592–95. The decision provided five criteria that judges could consider when confronted with the question of whether to admit scientific evidence. *Id.* at 593–94. *Daubert* is supposed to ensure that evidence is of a higher quality, or at least more thoroughly vetted than under *Frye v. United States* to be admitted. *See id.* at 596–97. *Daubert* requires trial judges to serve as a gatekeeper. *See* Lyn M. Gaudet, Note, *Brain Fingerprinting, Scientific Evidence, and Daubert: A Cautionary Lesson from India*, 51 JURIMETRICS 293, 296–98 (2011) [hereinafter Lyn M. Gaudet].

161. *Frye v. United States*, 293 F. 1013, 1014 (D.C. Cir. 1923), *superseded by* FED. R. EVID., *as recognized in Daubert*, 509 U.S. 579. “In *Frye*, the Court of Appeals . . . declined to admit expert testimony of the results of a systolic blood pressure deception test, finding the test itself, and therefore any expert opinions deduced from such a test, lacked sufficient standing and acceptance within the field to warrant admission.” Lyn M. Gaudet, *supra* note 160, at 297. The *Frye* standard, which became the standard followed by nearly all of the states for 70 years in determining the admissibility of scientific and expert evidence, was whether the expert's view or science in question was generally accepted in the relevant scientific community. *Id.* at 296–97.

162. *United States v. Day*, 524 F.3d 1361, 1369–70 (D.C. Cir. 2008) (affirming under *Daubert* exclusion of testimony of a neuroscientist expert who was going to testify to PET scan results and what they revealed about the defendant's voluntary and deliberate actions, concluding that the defendant's voluntary actions were substantially impaired and that he could not have purposely intended to break the law or appreciated the consequences of his actions; the court found the expert's conclusions were not supported by defendant's medical records or other psychiatric evidence); *United States v. Mezvinsky*, 206 F. Supp. 2d 661, 662, 671, 674–75 (E.D. Pa. 2002) (rejecting PET scan evidence and testimony as lacking both reliability and relevance in the prosecution of a former Congressman for fraud; where the defendant wanted to use the neuroimaging evidence of “frontal lobe organic brain damage” to argue he was unable to possess the requisite *mens rea* for the crimes alleged); *State v. Zimmerman*, 802 P.2d 1024, 1027–28 (Ariz. Ct. App. 1990) (finding sufficient evidence for the trial court's conclusion that BEAM analysis lacked support from the neurological community as a clinical, diagnostic tool and therefore finding the exclusion of BEAM evidence was not an abuse of discretion); *People v. Yum*, 3 Cal. Rptr. 3d 855, 856–57 (Cal. Ct. App. 2003) (Part 2–3 depublished) (affirming exclusion of expert evidence because the use of SPECT scan evidence to diagnose PTSD and brain trauma is not generally accepted in the field of brain imaging and neurology); *Protsman*, 105 Cal. Rptr. 2d at 822 (affirming trial court's exclusion of PET scan evidence used to diagnose head trauma because it did not pass the *Kelly* test, which requires a consensus in the relevant scientific community, because defense failed to demonstrate consensus in the neurology and brain imaging fields, while the prosecution's medical expert, after conferring with five other experts in the field, concluded that the use of PET scans in diagnosing head trauma was “investigational only

interpreted, and thus, they speak through experts.

In order for expert testimony to be admissible in certain jurisdictions, the expert's views must coincide with a generally accepted explanatory theory.¹⁶³ General acceptance has been explained by one court to be a "substantial agreement among a cross-section of the relevant scientific community" or "a consensus in the field,"¹⁶⁴ and the court's finding of the lack of such an agreement is often cited for denying the admissibility of neuroimaging evidence. For example, in 2003, a California court concluded in *People v. Yum* that a review of the relevant literature revealed that members of the "neurology and brain imaging community [did] not support the use of SPECT scans to diagnose prior head trauma and mental disorders like [post-traumatic stress disorder]"; in fact, the relevant community considered SPECT scans "generally unreliable for this purpose."¹⁶⁵

But later that year, a California court admitted SPECT scan evidence in another criminal case, *People v. Herrera*.¹⁶⁶ An expert witness for the defense, Dr. Amen, testified, "SPECT brain imaging is generally accepted in the medical and scientific community as a reliable forensic tool."¹⁶⁷ During cross-examination, Dr. Amen was asked about the consent form the defendant signed before receiving the SPECT exam that included the following: "[M]any physicians do not fully understand the application of SPECT imaging and may tell you that the technology is experimental."¹⁶⁸ Notwithstanding the recent ruling in *Yum*¹⁶⁹ and Dr. Amen's admission that there are members of the medical and scientific community that disagree

and had not been validated by the neurology and brain imaging community").

163. *E.g.*, *Zimmerman*, 802 P.2d at 1027 (citing *State v. Plew*, 745 P.2d 102, 104 (Ariz. 1987) (en banc)).

164. *Yum*, 3 Cal. Rptr. 3d at 857.

165. *Id.* at 856–57 (excluding SPECT scan and accompanying testimony because defense had not shown SPECT scans were generally accepted in the fields of brain imaging and neurology as a diagnostic tool for determining brain trauma and PTSD; their capacity as a diagnostic tool was limited to stroke, epilepsy, seizure, and dementia; all other uses were experimental); *see also Zimmerman*, 802 P.2d at 1028 (finding sufficient evidence for the trial court's conclusion that BEAM analysis lacked support from the neurological community as a clinical, diagnostic tool, and so the exclusion of BEAM evidence was not an abuse of discretion).

166. *People v. Herrera*, No. B163516, 2003 WL 22962809, at *1, *3 (Cal. Ct. App. Dec. 17, 2003) (citing *People v. Samayoa*, 938 P.2d 2, 34 (Cal. 1997)).

167. *Id.* at *4.

168. *Id.*

169. *Yum*, 3 Cal. Rptr. 3d at 856–57.

with the use of SPECT imaging to evaluate criminal defendants,¹⁷⁰ the court admitted the SPECT results and Dr. Amen's interpretation of the scan during the guilt phase of Herrera's trial.¹⁷¹

Two years later, another California court handled SPECT scan evidence differently yet again, further demonstrating the variability in how similar evidence is received by different trial courts.¹⁷² In the 2005 California case of *People v. Ford*, the trial court excluded SPECT scan evidence, but the appellate court found the exclusion was error.¹⁷³ The defense argued that the SPECT scan results would have given the jury a visual image of the defendant's brain impairments described in the medical expert's testimony and would have supported defendant's "contention that, as a result of his intoxication and brain impairments, he did not form the intent to kill or premeditate the shooting."¹⁷⁴ The appellate court ultimately determined any error in excluding the SPECT evidence was harmless because the medical expert was still allowed to testify and there was no reasonable probability that the jury's verdict would have been different had the SPECT scan results been admitted.¹⁷⁵ Despite the court's conclusion that the SPECT scan would not have had enough of an impact on the verdict to warrant a reversal on the trial court's ruling, it is relevant that the court found it could have been error

170. *Herrera*, 2003 WL 22962809, at *4.

171. *See id.* at *1. An unavoidable side effect of our adversarial system that allows parties to select their own experts is that the opinions the court receives are only as credible as the experts themselves. Dr. Amen is an example of a scientific expert who has been allowed to testify in a large number of cases when he is one of the most controversial figures in the professions of radiology and psychiatry. Neely Tucker, *Daniel Amen Is the Most Popular Psychiatrist in America. To Most Researchers and Scientists, That's a Very Bad Thing.*, WASH. POST (Aug. 9, 2012), https://www.washingtonpost.com/lifestyle/magazine/daniel-amen-is-the-most-popular-psychiatrist-in-america-to-most-researchers-and-scientists-thats-a-very-bad-thing/2012/08/07/467ed52c-c540-11e1-8c16-5080b717c13e_story.html. For over a decade he was allowed to testify in trials when he nor any other expert had published details on the diagnostic utility of SPECT scans. *See id.* Up until very recently Dr. Amen has kept all of his data proprietary. *See* Robert Burton, *Brain Scam*, SALON (May 12, 2008), http://www.salon.com/2008/05/12/daniel_amen/.

172. *See People v. Ford*, No. B111801, 2005 WL 236487, at *3, *7 (Cal. Ct. App. Jan. 25, 2005).

173. *Id.* at *7 (holding any error that resulted from the exclusion harmless).

174. *Id.* at *3.

175. *Id.* at *7 (citing *People v. Cudjo*, 863 P.2d 635, 651 (Cal. 1993) (en banc)) ("We conclude that any error in this regard was harmless because exclusion of the SPECT scan results did not prevent [the expert] from testifying to any of his findings or conclusions concerning appellant's brain damage and alcoholism.").

to exclude the evidence in the guilt phase.

SPECT scans are not the only neuroimaging procedure to be rejected initially by courts but then later accepted by the same or a different court, or to be admitted for some purposes and excluded for others. PET and BEAM analysis (of EEG data) have undergone similar scrutiny.¹⁷⁶ Some courts have refused to admit the scan results, citing failure to meet the general acceptance criteria of *Frye* or *Daubert*.¹⁷⁷ As discussed in the context of the *Gigante* case above, it is important to note that the problem courts have had is not with the neuroimaging procedures themselves but with the application of the brain scans as a diagnostic tool for certain conditions.¹⁷⁸ Other courts, however, have admitted PET and BEAM analysis in the guilt phase of the trial.¹⁷⁹ Other courts have not explicitly discussed admissibility standards for PET scans when evaluating a defendant's claim, deciding instead to discuss

176. See, e.g., *State v. Zimmerman*, 802 P.2d 1024, 1028 (Ariz. Ct. App. 1990) (rejecting BEAM analysis because not supported by scientific community).

177. *United States v. Montgomery*, 635 F.3d 1074, 1090 (8th Cir. 2011) (holding that although trial court erred by excluding expert's testimony on PET scan, which showed abnormalities, any error was harmless under *Daubert* because testimony had minimal probative value because PET scan was not used for the specific disease defendant claimed and abnormalities do not predict behavior); *Jackson v. Calderon*, 211 F.3d 1148, 1165 (9th Cir. 2000) (citation omitted) (affirming exclusion of PET scan under *Daubert*); *People v. Protsman*, 105 Cal. Rptr. 2d 819, 822–23 (Ct. App. 2001) (depublished) (affirming exclusion of PET scan evidence under California's equivalent to the federal *Frye* case, *People v. Kelly*, 549 P.2d 1240 (Cal. 1976), superseded by CAL. EVID. CODE § 351.1 (West 1983), as recognized in *People v. Wilkinson*, 94 P.3d 551 (Cal. 2004)). See generally *People v. Bowman*, No. B242467, 2014 WL 718416, at *6 n.2 (Cal. Ct. App. Feb. 26, 2014).

178. See *supra* notes 52–56 and accompanying text; see also, e.g., *People v. Hix*, No. B203884, 2009 WL 242318, at *6, *8 (Cal. Ct. App. Feb. 3, 2009) (attempting to introduce SPECT scan to show mental defect, thus preventing him from forming specific intent, but the court said that SPECT scans are not generally accepted in the neurological community to be reliable for showing brain damage, only for diagnosing dementia, epilepsy, and seizures). It is worth noting that in the same case, a court appointed neurologist conducted EEG and MRI testing, which were found to be normal. *Hix*, 2009 WL 242318, at *3.

179. See *People v. Musselwhite*, 954 P.2d 475, 482–83 (Cal. 1998) (noting trial court's admission of evidence regarding BEAM test results during guilt phase); *People v. Steele*, 47 P.3d 225, 232 (Cal. 2002) (noting trial court's admission of evidence regarding BEAM test results during guilt phase); *Commonwealth v. Trapp*, 668 N.E.2d 327, 332 (Mass. 1996) (evidence regarding BEAM test results used by the State during guilt phase), *habeas corpus dismissal aff'd* by *Trapp v. Spencer*, 479 F.3d 53 (1st Cir. 2007), *abrogated* by *Holland v. Florida*, 560 U.S. 631, 649 (2010), as recognized in *Holmes v. Spencer*, No. 15-1216, 2016 WL 2610658, at *2 n.1 (1st Cir. May 6, 2016).

the merits of the request.¹⁸⁰ For example, in the case of *Rogers v. State*, the Florida Supreme Court found “that the trial court did not abuse its discretion in denying [defendant’s] request for the PET-Scan” because the defendant had not established necessity of or the prejudice that resulted from not having a PET scan performed.¹⁸¹

One of the most recent opinions to discuss whether PET scan evidence is appropriate in the guilt phase as it relates to a defendant’s mental state answered the question in the negative. In the 2014 California opinion in *People v. Bowman*, the defendant argued the trial court erred in denying him the right to present a defense by applying the test established in *People v. Kelly* to the PET scan results and in excluding testimony of defense expert Dr. Arthur Kowell.¹⁸² The testimony was proffered as relevant to defendant’s deliberation and premeditation.¹⁸³ The appellate court rejected the defendant’s argument, explaining:

The evidence at the hearing was unequivocal in establishing the medical scientific community does *not* yet accept that PET scan results can provide information to the expert in a criminal case that may assist the jury in determining a defendant’s mental state After reviewing the relevant case law, we conclude the trial court properly applied the rationale in *Kelly* to exclude the results of the PET scan.¹⁸⁴

While failing the *Frye*, *Kelly*, or *Daubert* admissibility standards for scientific evidence is one way neuroimaging evidence can be deemed inadmissible, it is not the only way. A court may determine that an expert is not qualified to link the results of otherwise admissible neuroimaging evidence to the defendant’s behavior or mental state at a particular time,¹⁸⁵

180. See, e.g., *Hoskins v. State*, 702 So. 2d 202, 208–10 (Fla. 1997) (per curiam) (discussing relevance of mental condition and PET scan to defense’s case—not whether PET scan was generally accepted).

181. *Rogers v. State*, 783 So. 2d 980, 999–1000 (Fla. 2001) (per curiam).

182. *Bowman*, 2014 WL 718416, at *6 (citing *Kelly*, 549 P.2d 1240).

183. *Id.* at *6 n.3.

184. *Id.* at *12.

185. See, e.g., *United States v. Purkey*, 428 F.3d 738, 752 (8th Cir. 2005) (holding a nuclear medicine specialist was unqualified to connect his own testimony regarding the results of the PET and MRI tests he ran on the defendant to a conclusion about the defendant’s state of mind at the time of the offense); *People v. Brooks*, No. A124664, 2011 WL 5979668, at *9–10 (Cal. Ct. App. Nov. 30, 2011) (noting trial court’s disqualification of an expert because of its concerns “as to whether [the expert] is an

or that the expert testimony on the link between the brain and behavior is not definitive enough to warrant consideration by the court.¹⁸⁶ If timing is the issue, it could be the timing of the evaluation in regards to the crime or confession,¹⁸⁷ and if there is a long delay between the two events, such as a number of years, it may be determined that such a retrospective assessment of a defendant's thoughts and mental state is not proper.¹⁸⁸ Such was the case in *United States v. Purkey*.¹⁸⁹

Box 2: *United States v. Purkey*

Time Lag between Crime and Brain Scan

The Crime: While awaiting trial for the murder of a Kansas woman, Mr. Purkey asked to speak to detectives and an FBI agent about his involvement with a kidnapping and homicide that occurred earlier that year.¹⁹⁰ The meeting was arranged, and Purkey voluntarily waived his constitutional rights and confessed to the kidnapping, rape, murder, and dismemberment of the victim who was later identified as 16-year-old high school sophomore Jennifer Long.¹⁹¹ In exchange for his confession, Purkey sought assurances that the case would be federally prosecuted

independent and unbiased expert and truly represents a cross-section of the relevant scientific community”).

186. See, e.g., *State v. Idellfonso-Diaz*, No. M2006-00203-CCA-R9-CD, 2006 WL 3093207, at *1, *2, *3, *4 (Tenn. Crim. App. Nov. 1, 2006). In *Idellfonso-Diaz*, a psychiatric evaluation of the defendant included an MRI, PET, and EEG; the PET scan revealed a mild brain abnormality. *Id.* at *1–2. A defense expert testified that the defendant had a reduced ability to premeditate the crimes. *Id.* at *2. The appellate court overturned the trial court's decision to include the expert's testimony, classifying the testimony as irrelevant and inadmissible because the expert was not able to say that as a result of the brain deficits the defendant completely *lacked* the capacity to premeditate, because testifying to a *reduced ability* was not sufficient. *Id.* at *4; see also *Brooks*, 2011 WL 5979668, at *11–13 (denying admission of the SPECT evidence because the defendant's expert had questionable impartiality, the defendant failed to show general acceptance for that particular application of SPECT, and the evidence had low probative value since it only confirmed the neuropsychologist's conclusions).

187. See, e.g., *Idellfonso-Diaz*, 2006 WL 3093201, at *1.

188. See, e.g., *Purkey*, 428 F.3d at 753.

189. See *infra* Box 2.

190. *Purkey*, 428 F.3d at 745.

191. *Id.*

because he wished to serve his time in a federal, not state, penitentiary.¹⁹² But at trial, Purkey changed his story.¹⁹³ He claimed that he did not kidnap Ms. Long but that she voluntarily accompanied him to his home.¹⁹⁴ Purkey claimed that he made up the kidnapping part of his story when he talked to the detectives because he knew that would ensure the FBI's involvement and federal prosecution of the case.¹⁹⁵

The Neuroimaging Evidence: During the guilt phase, the defendant wanted Dr. David Preston, a nuclear medicine specialist, to testify to MRI and PET scan results, which indicated abnormalities, to refute his intent to kidnap and to provide insight as to his state of mind when he confessed to detectives.¹⁹⁶

The Result: The court excluded the scan results and testimony.¹⁹⁷ The court reasoned that while Dr. Preston was qualified to testify to the results of the scans, he was not qualified to speculate as to defendant's state of mind at the time of the offenses or when he confessed.¹⁹⁸ The doctor's report did not attempt to tie the test results to the offenses and the doctor admitted the images produced by the tests could not predict behavior nor did they have a causal relationship to criminal behavior.¹⁹⁹ The court held the evidence was properly excluded by the trial court.²⁰⁰ A jury found Purkey guilty of the kidnapping, rape, and murder of Jennifer Long and recommended a sentence of death, which was affirmed by the Eighth Circuit.²⁰¹

Another reason for rejecting the admission of otherwise generally accepted evidence is that the evidence is not relevant to the legal questions at issue. For example, in the context of the insanity defense, courts have

192. *Id.*

193. *Id.* at 745–46.

194. *Id.*

195. *Id.* at 746.

196. *Id.* at 752.

197. *Id.*

198. *Id.* at 752–53.

199. *Id.* at 753.

200. *Id.*

201. *Id.* at 745–46, 764.

refused to admit neuroimaging evidence because the results of the brain scan would allegedly not shed any light on the legal issue in question.²⁰² This was the opinion of the court in *People v. Goldstein*,²⁰³ the New York “subway killer” case, in which the defense sought to introduce PET scan data in support of Goldstein’s claim of insanity specifically to support his diagnosis of schizophrenia.²⁰⁴ Declining to admit the PET scan results, the court explained that regardless of what the PET scan showed, it was not relevant to the legal issue of insanity since the presence of mental illness does not prevent one from being legally sane.²⁰⁵ While that is technically true since insanity is a legal construct, mental health professionals would likely argue that the presence of mental illness is clearly relevant to an insanity inquiry because there are many types and symptoms of mental illness that can have direct bearing on an individual’s ability to perceive accurately and respond appropriately to his or her environment. So the presence or absence of mental illness can make it more or less likely that an individual would be able to satisfy the particular requirements of the applicable legal sanity standard.

Box 3: *People v. Goldstein*

Neuroimaging Evidence Not Relevant for Proving Insanity

The Crime: In 1999, Andrew Goldstein, a schizophrenic, pushed a woman off a New York City subway platform directly into an oncoming train.²⁰⁶ The woman was dragged under the train and died from her injuries.²⁰⁷ The case caused alarm throughout the city and received widespread media attention.²⁰⁸

202. *E.g.*, *People v. Goldstein*, 786 N.Y.S.2d 428, 432 (App. Div. 2004) (excluding PET scan results because they were not probative of insanity issue), *rev’d by* 843 N.E.2d 727 (N.Y. 2005).

203. *Id.*; *see infra* Box 3.

204. *Goldstein*, 786 N.Y.2d at 429, 432.

205. *Id.* at 432.

206. *Id.* at 429.

207. Edie Magnus, *A Deadly Encounter*, DATELINE NBC (Jan. 20, 2007), http://www.nbcnews.com/id/16713078/ns/dateline_nbc/t/deadly-encounter/#.V2jDYakWV4.

208. Anemona Hartocollis, *Nearly 8 Years Later, Guilty Plea in Subway Killing*, N.Y. TIMES (Oct. 11, 2006), http://www.nytimes.com/2006/10/11/nyregion/11kendra.html?_r

The Neuroimaging Evidence: As part of a psychiatric evaluation, Goldstein received a PET scan.²⁰⁹ Goldstein argued that the PET scan results, which revealed a “massive reduction in metabolism in the frontal lobe and the basal ganglia,” provided support for his diagnosis of schizophrenia and therefore supported his insanity defense.²¹⁰ The court disagreed that the PET scan abnormality was relevant to the issue of insanity and believed it was unnecessary to corroborate the psychiatric diagnosis because the fact that Goldstein was a schizophrenic was not disputed; indeed, a State medical expert testified to that diagnosis.²¹¹ The trial court excluded the PET scan results.²¹²

The Result: On appeal, it was determined that the PET scan evidence was properly excluded by the trial court.²¹³ The test results could not conclusively prove schizophrenia, only identify an abnormality in the brain.²¹⁴ Even if the brain abnormality was able to prove that the defendant suffered from schizophrenia, it would not address the concept of legal insanity because a person with mental illness is not precluded from understanding the nature and consequences of his or her actions.²¹⁵ Therefore, the court found that the PET scan evidence was not probative of the issue in question.²¹⁶ Goldstein’s first trial ended with a mistrial because of a hung jury, and the second trial ended with a conviction of murder-two, but that conviction was overturned by the state’s highest court; after that, Goldstein accepted a plea agreement for manslaughter: 23 years in exchange for a guilty plea.²¹⁷

c. Prosecution’s reliance on neuroimaging evidence. Occasionally a brain scan of the defendant does not reveal any visible abnormality or

=0.

209. *Goldstein*, 786 N.Y.S.2d at 432.

210. *Id.*

211. *Id.*

212. *Id.*

213. *Id.*

214. *Id.*

215. *Id.*

216. *Id.*

217. Magnus, *supra* note 207.

impairment. In some such cases, the lack of any evident brain damage in a brain scan can be fatal to a defendant's argument.²¹⁸ In other cases, the defense might argue that the defendant nevertheless suffers from organic brain damage and seek to explain away the negative result using expert testimony.²¹⁹ In a few cases, the prosecution has proffered neuroimaging evidence to refute one of the defense's arguments.²²⁰ In 1996, the State of Massachusetts used results from a BEAM analysis previously conducted by defense counsel, which did not reveal any brain abnormalities, to undermine the defendant's argument that he had a brain defect.²²¹ Similarly, in the 1999 Florida case of *Bates v. State*, the State requested the defendant undergo an MRI, the request was granted, and the State used the negative MRI results to rebut the defense's assertion that organic brain damage negated intent and premeditation.²²²

218. See, e.g., *State v. Ejonga*, No. 70069-3-I, 2015 WL 3385114, at *6 (Wash. Ct. App. May 26, 2015) ("[The expert witness] finished his opinion before the electroencephalogram (EEG) or the magnetic resonance imagery (MRI) results were known."), *petition for review denied*, 184 Wash. 2d 1027 (2016).

219. See, e.g., *People v. Salcido*, 186 P.3d 437, 457–58 (Cal. 2008) (arguing that despite "generally normal" MRI, EEG, and CAT scan results, defendant had a vulnerable mental state and suffered a psychotic episode that explained the crime); *State v. DeJesus*, 672 A.2d 488, 494 & n.13 (Conn. 1996) (arguing organic brain damage as part of an insanity defense even though MRI results were negative; defense expert argued that an MRI would not be able to detect the defendant's microscopic brain damage).

220. Two of these are older cases. *United States v. Bramlet*, 820 F.2d 851, 853–54 (7th Cir. 1987) (allowing prosecution expert to testify that normal CT, x-ray, and EEG were evidence that defendant was not suffering from organic brain damage); *State v. Hollis*, 731 P.2d 260, 269 (Kan. 1987) (arguing insanity defense based on expert testimony of an organic brain syndrome that impaired defendant's judgment; in rebuttal the State had EEG and CT performed, both of which showed no abnormalities).

221. *Commonwealth v. Trapp*, 668 N.E.2d 327, 332 (Mass. 1996). In response to this evidence introduced by the State, the defense had experts testify to a CT scan that indeed revealed an organic brain abnormality, which was a result of head trauma, and the defense explained the negative BEAM analysis results by pointing out that a BEAM only measures activity on the surface of the brain and the defendant's defect is deep within his brain, so a BEAM analysis would not be able to reflect it. See *Trapp v. Spencer*, 479 F.3d 53, 56 n.1 (1st Cir. 2007) (reviewing defendant's petition for writ of habeas corpus), *abrogated by* *Holland v. Florida*, 560 U.S. 631, 649 (2010), *as recognized in* *Holmes v. Spencer*, No. 15-1216, 2016 WL 2610658, at *2 n.1 (1st Cir. May 6, 2016). On appeal, the defendant objected to the State's use of the BEAM results, but the court decided there had been no prejudice because the results were used in rebuttal to the testimony of defense experts. *Id.* at 57 n.3.

222. *Bates v. State*, 750 So. 2d 6, 15–16 (Fla. 1999) (per curiam).

2. Requests to Obtain a Brain Scan

A second set of cases relating to the guilt phase involves those where the defendant sought funds from the court for neuroimaging or sought a continuance or stay of the trial in order to obtain a brain scan.²²³ The posture of the funding request cases are such that, in those cases where the trial court grants funds for a brain scan, there is unlikely to be any appeal and thus, no reported opinion. Therefore, the only cases reported are those where the defendant was originally denied funding by the trial court and has appealed that decision to an appellate court. Only a small number of reported cases have overturned the original denial of funding and granted on appeal a defendant's request for funds for brain scan testing. Like the denial of a request for other types of testing, a trial court's denial of funds for a scan will not be overturned absent an abuse of discretion.²²⁴ Given this deferential review, it is perhaps not surprising that appellate courts uphold the vast majority of lower court decisions denying funding for brain scans, while overturning the lower court and authorizing funding in only a small number of cases.

Courts may differentiate between funds to rebut the State's forensic evidence or general evaluations and funds for expert assistance.²²⁵ It is much easier for the defense to be granted funds for general tests than it is to be granted funds for expert evaluations and testimony.²²⁶ In order for defendants to be entitled to expert funds at a state's expense, in some jurisdictions they must establish that the expert will assist the defense and that the denial of expert assistance would result in an unfair trial.²²⁷ To prove an unfair trial, the expert must be necessary to establish an aspect of the defense or rebut an issue or claim made by the prosecution.²²⁸ It is up to the

223. See Appendix A, *supra* note 2.

224. *Smith v. Kearney*, No. 2 CA-SA 2008-0019, 2008 WL 2721155, at *1, *4-5 (Ariz. Ct. App. July 11, 2008) (finding no abuse of discretion in trial court's denial of defendant's request for funds for a PET scan).

225. See *Burgess v. State*, 827 So. 2d 134, 150-52 (Ala. Crim. App. 1998).

226. See *id.* (dismissing defendant's argument that he was not given enough funds for psychological testing, including an MRI, as an issue without merit because he had never made a specific request for funds for a psychological examination or MRI and the defendant had been granted \$1,000 to counter the State's anticipated presentation of forensic evidence); *Bates*, 750 So. 2d at 16-17 (finding denial of defendant's request for additional scans and expert assistance to help determine whether he had functional brain damage was not an abuse of discretion).

227. *Burgess*, 827 So. 2d at 150.

228. See *Ake v. Oklahoma*, 470 U.S. 68, 86-87 (1985).

defendants to articulate to the court exactly why the testing is necessary and how denial of such testing precludes their ability to receive a fair trial.²²⁹

In a handful of cases, the defendant had already received a scan of some kind but sought funding for additional neuroimaging. Only two cases were identified where a defendant had a brain scan and then sought additional brain scans to be admitted in the guilt phase,²³⁰ while three defendants sought additional testing to use as mitigating evidence in the penalty phase.²³¹ Because of the small number of cases, these five cases are

229. *Id.* at 84. *Ake* supports a constitutional right to expert assistance for indigent defendants but only if a defendant makes a showing that his or her sanity at the time of the crime is going to be a significant issue at the trial. *Id.* at 83–84. And in the event that a defendant exhibits clear indications of mental retardation or brain damage, due process can require an adequate examination by qualified mental health experts. *See State v. Sireci*, 536 So. 2d 231, 233 (Fla. 1988) (per curiam).

230. *Dirickson v. State*, 953 S.W.2d 55, 56–58 (Ark. 1997) (denying requests of defendant who was evaluated by state hospital, received initial CAT scan, MRI, and EEG, and then requested a continuance and funds so he could obtain additional testing to further investigate a congenital brain defect and its potential value in support of a mental disease or defect defense, because he had already had a series of tests and a neurologist review them, he had received what he was entitled to, and the court was not required to let him doctor shop until he found one that supported his defense); *People v. Pickens*, 521 N.W.2d 797, 813 (Mich. 1994) (arguing the trial court's denial of independent defense neurological tests mandated reversal of conviction). Defendant had a CAT scan done for his insanity defense and wanted another one performed. *Pickens*, 521 N.W.2d at 811, 813 n.36. The court stated that although the trial court violated the statute by not allowing the defense an independent test, it was not a miscarriage of justice because the defense expert still concluded mental illness from the information available. *Id.* at 813.

231. *Rogers v. State*, 783 So. 2d 980, 998–99 (Fla. 2001) (per curiam) (finding no abuse of discretion when the lower court denied defendant's request for a PET scan when the defendant had already been given \$1,500 to undergo an MRI and the results were normal and the defendant was unable to demonstrate prejudice as a result of the denial of the additional scan); *Holland v. State*, 705 So. 2d 307, 318, 334 (Miss. 1997) (en banc) (finding additional brain scans were unnecessary after defendant's EEG was normal because the defendant had not shown a "substantial need" for the testing but only offered undeveloped assertions and the court would not allow the defendant to go on a "fishing expedition"); *Gallego v. State*, 23 P.3d 227, 242 (Nev. 2001) (en banc) (finding additional brain scan testing unwarranted because a CAT scan of defendant's brain revealed significant damage and a doctor already testified to that brain damage), *abrogated by Nunnery v. State*, 263 P.3d 235 (Nev. 2011) (en banc). The defense argued the negative MRI results made a PET scan imperative because the jury would be misled by the lack of results from the MRI and would underestimate the extent of Rogers' brain damage. *Rogers*, 783 So. 2d at 989. A medical expert for the defense testified that a PET scan would be necessary to confirm Rogers' seizure disorder, which could be considered

grouped together here. In all five cases, the defendants' requests were not granted. From this limited sample, it appears that such requests are likely to be denied by the court, regardless of whether the defendant's original scan was normal or revealed brain damage. If the first test was normal, then a defendant cannot establish the particularized need required for further testing; and if the first test revealed damage, then the results and testimony were likely already admitted, rendering any additional results and testimony merely cumulative. This "cumulative" theme can be used by courts to deny defendants' claims in the guilt and even penalty phase because additional tests that could confirm the presence of brain damage already known to, presented to, and considered by the court do not add anything new to the defendant's case. An example of such a decision is *Dirickson v. State*.²³²

Box 4: *Dirickson v. State*

No Funding for Second Round of Brain Scans

The Crime: Under the influence of alcohol, naked, and armed with a hunting knife, Albert Allen Dirickson broke into the home of a DeQueen, Arkansas, family and attempted to rape the woman living there, stabbing her and her sons in the process.²³³

The Trial: Dirickson was charged with and convicted of three counts of attempted capital murder, attempted rape, and residential burglary.²³⁴ "He was sentenced to . . . 140 years' imprisonment for the offenses."²³⁵ Dirickson's defense was diminished capacity as a result of mental disease or defect.²³⁶ Dirickson had been diagnosed with an "agenesis of the corpus callosum" and made repeated requests for a continuance and requested funds to pursue additional brain scan testing to investigate further this abnormality and its potential value in support of his mental disease or

a non-statutory mitigating factor. *Id.* The trial judge denied the request for a PET scan explaining that the seizure disorder had been previously diagnosed so it could be established through medical records if the defense desired to have it be considered a mitigating factor; the brain scan was not necessary for that purpose. *Id.*

232. *Dirickson*, 953 S.W.2d at 56.

233. *Id.*; see *infra* Box 4.

234. *Dirickson*, 953 S.W.2d at 56.

235. *Id.*

236. *Id.*

defect defense.²³⁷ The trial court denied his requests.²³⁸

The Neuroimaging Evidence: Dirickson received a CAT scan from the state hospital.²³⁹ The doctor that interpreted the CAT scan recommended Dirickson be evaluated by a neurologist.²⁴⁰ Later in the state hospital, Dirickson received an MRI, an EEG, and a full neurological evaluation.²⁴¹ The neurologist report indicated that Dirickson's agenesis of the corpus callosum was an "incidental congenital abnormality" that would not have influenced Dirickson's mental state or criminal behavior.²⁴²

The Appeal: On appeal, Dirickson relied on *Ake v. Oklahoma* (which held that "when a defendant makes a preliminary showing that his sanity is likely to be a significant factor at trial," the Constitution requires the state to ensure the defendant has access to a competent psychiatrist and appropriate evaluation) to argue that the trial court erred in denying his requests for funds and additional neurological testing because it was critical to his defense.²⁴³

The Result: The Court found *Ake* indeed applied and that its requirements had been satisfied.²⁴⁴ The defendant received a full mental examination, a total of three brain scans, and had his record reviewed by a neurologist.²⁴⁵ The state was not required to permit the defendant access to more than one psychiatrist or multiple mental examinations until he received the results or diagnosis he wanted.²⁴⁶ One complete examination is required; a second opinion is not.²⁴⁷ Because the defendant received appropriate examinations at the state hospital, his motions requesting

237. *Id.* at 57.

238. *Id.*

239. *Id.* at 56.

240. *Id.*

241. *Id.* at 56–57.

242. *Id.* at 57.

243. *Id.* (citing *Ake v. Oklahoma*, 470 U.S. 68 (1985)).

244. *Id.*

245. *Id.* at 56–57.

246. *See id.* at 57 ("[T]he State is not required to pay for a defendant to shop from doctor to doctor until he finds one who will declare him incompetent to proceed with his trial.").

247. *Id.*

continuance and additional funds were properly denied by the trial court.²⁴⁸

A related set of cases involve defendants seeking a delay in the trial in order to obtain a brain scan. Like in many areas of the law, appellate courts will overturn the trial court's denial of a defendant's request for leave of court or continuance to obtain brain scan testing only if the trial court showed an abuse of discretion.²⁴⁹ Generally, the defendant is required to demonstrate particularized need in order for the court to grant a request for testing.²⁵⁰ Many courts use a two-pronged test that requires the defendant to demonstrate prejudice in addition to particularized need. For example, the Florida Supreme Court applied the two-pronged test in its 2002 decision in *Bottoson v. State* to deny the defendant's request for leave of court to obtain brain scans because Bottoson failed both prongs of the test.²⁵¹ He wanted a PET or SPECT scan to see if he had brain damage, which is akin to a fishing expedition and exactly what is not allowed, and he had not linked his alleged need for the scans or his alleged brain damage to any of his substantive claims; therefore, he could not be prejudiced by the denial of the request for testing.²⁵²

An additional concern that can play a role in a court's denial of a request for a scan may be a timing issue: it may be too late.²⁵³ In a 1995 California case, a defendant was granted a continuance by the court to have a brain scan—which he did—but he did not have an expert evaluate the scan

248. *Id.* at 58.

249. *Bottoson v. State*, 813 So. 2d 31, 34 (Fla. 2002) (per curiam).

250. *See United States v. Phillips*, No. 89-5686, 1990 WL 92625, at *2 (6th Cir. July 3, 1990) (per curiam) (finding the trial court did not abuse its discretion by denying defendant's motion for a second psychiatric evaluation or for a BEAM test because he could not show what the test and expert services would add to those previously conducted; he failed to show how the services were necessary to his defense).

251. *Bottoson*, 813 So. 2d at 34–35. Under Florida law, courts “consider the following two factors: (1) if the defendant established a particularized need for the test; and (2) if the defendant was prejudiced by the trial court's denial of the motion requesting a PET-scan.” *Id.* at 34 (citing *Rogers v. State*, 783 So. 2d 980, 988–99 (Fla. 2001) (per curiam)).

252. *Id.*

253. *United States v. Fisher*, 10 F.3d 115, 118 (3d Cir. 1993) (denying Fisher's request for a continuance to receive an EEG, CAT scan, or MRI because an expert already testified as to Fisher's organic brain damage, and it was too late and unnecessary for Fisher to look for support of his claim of brain damage with a brain scan).

despite having ample time to do so.²⁵⁴ Consequently, the defendant was unable to get his PET scan results admitted into the guilt and penalty phases of the trial, so he sought a new trial, arguing the brain scan results constituted newly discovered evidence—an argument that the court rejected.²⁵⁵ In the only other case where a defendant's request for a brain scan was granted—a New York case from 1994—the court found that neurological testing was necessary to investigate potential brain damage that may have played a role in the defendant's response to a threatening situation, as that evidence would be potentially relevant to his justification defense.²⁵⁶

3. *Ineffective Assistance of Counsel*

The Supreme Court's decision in *Strickland v. Washington* is the leading case on ineffective assistance of counsel (IAC) claims.²⁵⁷ The cases involving neuroimaging evidence and IAC claims are all analyzed using the criteria set forth in *Strickland*. For a claim of IAC to be successful, two requirements must be satisfied: (1) the claimant must identify particular acts or omissions of the lawyer that are outside of the broad range of reasonably competent performance under prevailing professional standards, and (2) the deficiency shown must be demonstrated to have so affected the fairness and reliability of the proceeding that confidence in the outcome is undermined.²⁵⁸ A court presented with an IAC claim is not required to “make a specific ruling on the performance component of the test when it is clear that the prejudice component is not satisfied.”²⁵⁹ A defendant advancing an IAC claim needs to establish that but for the deficiencies of counsel, there would have been a different outcome in the sentencing phase.²⁶⁰ When reviewing an IAC claim, it is not the court's job to “retrospectively second-guess defense counsel's [strategic] decisions made [during] the stress [and chaos]

254. *People v. Beeler*, 891 P.2d 153, 183–84 (Cal. 1995) (en banc), *abrogated on other grounds by Crawford v. Washington*, 541 U.S. 36 (2004), *as recognized in People v. Pearson*, 297 P.3d 793 (Cal. 2013).

255. *Id.* at 183–85.

256. *People v. Jones*, 620 N.Y.S.2d 656, 657 (App. Div. 1994), *aff'd by* 654 N.E.2d 1209 (N.Y. 1995). To support his request for testing, the defendant had reports indicating he suffered a traumatic head injury as a child that may have caused permanent brain damage. *Id.*

257. *See Strickland v. Washington*, 466 U.S. 668 (1984).

258. *Id.* at 667–68 (citing U.S. CONST. amend. VI).

259. *Taylor v. State*, 3 So. 3d 986, 995 (Fla. 2009) (per curiam).

260. *People v. Musselwhite*, 954 P.2d 475, 502 (Cal. 1998).

of a trial.”²⁶¹ Deference will be given to defense counsel’s decisions if they can be considered reasonable trial strategy.²⁶²

Defendants can claim IAC for a myriad of reasons. As it relates to neuroimaging evidence in the guilt phase, a defendant can claim counsel was ineffective because counsel either did not pursue brain scanning at all, did not pursue additional testing, or did not call certain experts to testify to the scan results.²⁶³ Only one of the cases claiming IAC in the guilt phase was successful. The successful claim was in the case of *Hurles v. Ryan*, where the defendant claimed IAC for failure to conduct an adequate guilt phase investigation.²⁶⁴ Trial counsel requested funds for a brain scan, but the request was denied.²⁶⁵ After the guilt phase but before sentencing, the court granted funds, and the scan showed brain abnormality.²⁶⁶ The State took advantage of the lack of “objective” evidence of brain disorder, and so defense counsel was deficient for not raising the issue on appeal.²⁶⁷

In the majority of the remaining cases, IAC claims failed because the appellate court determined there was no prejudice to the defendant and no likelihood of a different outcome even if the neuroimaging evidence had

261. *Id.* at 501.

262. *See Strickland*, 466 U.S. at 681 (“Because advocacy is an art and not a science, and because the adversary system requires deference to counsel’s informed decisions, strategic choices must be respected in these circumstances if they are based on professional judgment.” (citation omitted)); *see also Taylor*, 3 So. 3d at 996 (“This Court has also held that trial counsel cannot be deemed ineffective simply because post-conviction counsel now disagrees with trial counsel’s strategy . . .” (citations omitted)).

263. *See Commonwealth v. Yancy*, 797 N.E.2d 371, 378 (Mass. 2003). The court rejected defendant’s IAC claim for failure to call Dr. Hill, the medical expert who administered the SPECT scan, because it was unlikely that Dr. Hill’s testimony was going to affect the verdict. *Id.* Furthermore, Dr. Hill’s report was admitted into evidence, another medical expert testified to the scan results and defendant’s brain deficits, and Dr. Hill’s testimony could have damaged the defendant as much as helped him. *Id.* at 377; *see also State v. Hering*, No. 04-1222, 2005 WL 2756388, at *4 (Iowa Ct. App. Oct. 26, 2005) (refusing to find ineffective assistance of counsel for failure to get an MRI of defendant prior to trial), *vacated by* No. 04-1222, 2006 WL 60678 (Iowa Jan. 11, 2006) (mem.) (preserving “defendant’s claims of ineffective assistance of counsel for a possible postconviction relief proceeding.” (citation omitted)); Appendix A, *supra* note 2.

264. *Hurles v. Ryan*, 752 F.3d 768, 781–82 (9th Cir. 2014) (addressing IAC claims against trial counsel and appellate counsel but only holding appellate counsel’s deficiencies reversible error).

265. *Id.* at 782.

266. *Id.*

267. *Id.* at 783.

been collected or introduced.²⁶⁸ One case involved an IAC claim relating to the failure to have an MRI read, but the court found there were no allegations the petitioner, a 15-year-old student who shot 15 people at his school, killing two and wounding 13, suffered from a mental disease or defect.²⁶⁹ The petitioner claimed the MRI results could have helped determine whether the young defendant's brain reflected a lack of development and impulse control that could have helped support defenses based on insanity, diminished capacity, or lack of intent.²⁷⁰ The court noted that this claim assumed the MRI would provide insight into the young man's condition that was relevant to his culpability or his ability to enter a guilty plea and that there was no other evidence to support such a claim.²⁷¹ The court pointed out the young man did not have a history of seizures or other serious medical conditions and, most importantly, the petitioner failed to prove that the MRI was not among the medical records reviewed during his examination by the psychiatrist.²⁷² In the guilt phase, as in other phases of a trial, normal results of brain scan procedures would likely remove any potential duty defense counsel may have of pursuing further testing.²⁷³ If there is no outside indication of mental disease or defect, as in the case of the 15-year-old defendant, there does not seem to be a duty to have even available brain scans read.²⁷⁴

IAC claims based on failure to obtain brain scans to confirm psychiatric diagnoses can be similarly unsuccessful. A few cases involved requests for

268. *E.g.*, *Jackson v. Norris*, 468 F. Supp. 2d 1030, 1042 (E.D. Ark. 2007), *vacated by* 256 F. App'x 12 (8th Cir. 2007) (per curiam); *Hering*, 2005 WL 27566388, at *4–5; *Yancy*, 797 N.E.2d at 378; *Zink v. State*, 278 S.W.3d 170, 185 (Mo. 2009) (en banc); *State v. Johnston*, 957 S.W.2d 734, 752–53 (Mo. 1997) (en banc).

269. *Williams v. Ryan*, No. 05cv0737-WQH (WMC), 2010 WL 3768151, at *1, *17 (S.D. Cal. Sept. 21, 2010), *aff'd by* 472 F. App'x 457 (9th Cir. 2012).

270. *Id.* at *5.

271. *Id.* at *13.

272. *Id.* at *13, *17.

273. *Norris*, 468 F. Supp. 2d at 1041–42 (rejecting IAC claim explaining there was nothing in the record that would have prompted further investigation by trial counsel because defendant merely made a conclusory argument that if an MRI, PET, or CAT scan had been performed, organic deficits might have been revealed); *Johnston*, 957 S.W.2d at 753 (explaining that because the initial tests—an EEG and standard neuropsychological testing—were normal, counsel was not ineffective for failing to pursue further, more detailed testing).

274. *See Williams*, 2010 WL 3768151, at *17 (“[T]here are no factual allegations that the MRI reveals that Petitioner had an undiagnosed mental defect or disease which would support a mental defense . . .”).

scans to bolster an insanity or diminished capacity defense. In the 2005 case of *State v. Hering*, the petitioner claimed IAC for failure to get an MRI of the defendant prior to trial.²⁷⁵ The petitioner argued the MRI could have revealed a loss of tissue to support his diagnosis of schizophrenia and show his brain did not function normally.²⁷⁶ The court explained that even if an MRI had shown tissue loss, it would not have affected expert testimony that Hering was legally sane at the time of the crime, so there was no prejudice and no likelihood of a different outcome had he received an MRI.²⁷⁷ In the 2009 Missouri case *Zink v. State*, a jury convicted the petitioner of first-degree murder.²⁷⁸ On appeal, the petitioner claimed IAC for failure to obtain a PET scan to confirm diagnoses of petitioner's personality disorders in support of a defense of diminished capacity.²⁷⁹ The petitioner claimed that even though a psychologist testified in his defense, the psychologist's findings did not have the "concrete verifiability of 'hard' sciences" and that a PET scan and medical doctor's testimony would offer "'hard' scientific evidence to confirm his 'soft' science diagnoses."²⁸⁰ Undermining Mr. Zink's claims, however, psychiatrists and psychologists testified that a PET scan would not be able to provide irrefutable evidence of his personality disorders or even identify the specific brain deficits or areas of the brain involved; the science was simply not that advanced.²⁸¹ The trial court found that "counsel's decision not to order the PET scan was reasonable and strategic."²⁸² Taking its analysis one step further, the court concluded that even if the scan had revealed abnormalities, the scan results would not have been admissible during the guilt phase of the trial because there was no generally accepted scientific link between the defendant's brain abnormalities and his diagnosed personality disorders.²⁸³

275. *State v. Hering*, No. 04-1222, 2005 WL 2756388, at *2 (Iowa Ct. App. Oct. 26, 2005), *vacated by* No. 04-1222, 2006 WL 60678 (Iowa Jan. 11, 2006) (mem.).

276. *Id.* at *4.

277. *Id.* at *5.

278. *Zink v. State*, 278 S.W.3d 170, 175 (Mo. 2009) (en banc).

279. *Id.* at 177.

280. *Id.* at 179.

281. *Id.*

282. *Id.* at 178.

283. *Id.* at 180. Putting the final nail in the coffin of Mr. Zink's argument for a PET scan, the court explained that even if the scan results were admissible they would have needed to establish that the personality disorders he suffered from caused him to act without deliberation in order for the outcome of the trial to have been any different. *Id.* This would have been nearly impossible since there was "overwhelming" evidence of deliberation in Mr. Zink's execution of the murder. *Id.* at 181.

B. Penalty

“Clearly, the existence of brain damage is a factor which may be considered in mitigation.”²⁸⁴

It is a well-known truism that the most important stage of a capital case is the sentencing phase. As many courts have pointed out, “death is different.”²⁸⁵ Consequently, the rules in the penalty phase of a capital case are also different. A defendant charged with a capital offense has the right to present virtually any evidence in mitigation during the penalty phase, and courts are constitutionally required to consider any relevant mitigating evidence.²⁸⁶ Indeed, to deny a defendant the opportunity to present a comprehensive case of mitigating evidence in the penalty phase is to violate his or her due process rights.²⁸⁷ When the question of admissibility of mitigating evidence arises, a court must keep these due process considerations in mind and be circumspect about excluding any such evidence.²⁸⁸ Because of the inclusive nature of admissibility rules during the

284. *Robinson v. State*, 761 So. 2d 269, 277 (Fla. 1999) (per curiam) (citing *DeAngelo v. State*, 616 So. 2d 440, 442 (Fla. 1993) (per curiam)).

285. *Ford v. Wainwright*, 477 U.S. 399, 411 (1986) (plurality opinion) (citing *Woodson v. North Carolina*, 428 U.S. 280, 305 (1976) (plurality opinion)) (stating “the penalty of death is qualitatively different from a sentence of imprisonment, however long”).

286. *See Ford*, 477 U.S. at 413 (plurality opinion) (stating “we have forbidden States to limit the capital defendant’s submission of relevant evidence in mitigation of the sentence”); *Lockett v. Ohio*, 438 U.S. 586, 604 (1978) (plurality opinion) (stating “the sentencer . . . [must] not be precluded from considering . . . any aspect of a defendant’s character or record . . . that the defendant proffers as a basis for a sentence less than death” (footnotes omitted)); *see also Hitchcock v. Dugger*, 481 U.S. 393, 398–99 (1987) (holding death sentence invalid when mitigating evidence excluded); *Bryan v. Mullin*, 335 F.3d 1207, 1225, 1230 (10th Cir. 2003) (Henry, J., concurring and dissenting) (disagreeing with majority and instead finding IAC claim for failure to present mitigating evidence despite client’s unreasonable wishes).

287. *Skipper v. South Carolina*, 476 U.S. 1, 5 n.1 (1986) (citing *Gardner v. Florida*, 430 U.S. 349, 362 (1977) (plurality opinion)); *State v. Mercer*, 672 S.E.2d 556, 562 & n.7 (S.C. 2009).

288. *Mercer*, 672 S.E.2d at 562 (explaining that the court’s interest in evidentiary matters must not overshadow the defendant’s due process rights to be able to fully present mitigating evidence); *see also Skipper*, 476 U.S. at 5 n.1 (“[I]t is also the elemental due process requirement that a defendant not be sentenced to death ‘on the basis of information which he had no opportunity to deny or explain.’” (citation omitted)). The *Mercer* court stressed, “Application of Rule 403 should be cautiously invoked against a capital defendant in the penalty phase, especially in light of the due process implications at stake when a capital defendant seeks to introduce mitigation evidence.” 672 S.E.2d at

penalty phase, neuroimaging evidence has been admitted as mitigating evidence in numerous capital cases.²⁸⁹

A court must consider both statutory and non-statutory mitigating circumstances in determining whether the death penalty is appropriate in a given case.²⁹⁰ A criminal defendant who wishes to establish brain damage as a mitigating factor can do so through expert testimony alone or expert testimony coupled with neuroimaging evidence.²⁹¹

In states that provide statutory mitigating factors, neuroimaging evidence and accompanying testimony are typically used to support either the factor of extreme emotional disturbance or the defendant's inability to appreciate the wrongfulness of the defendant's actions and an inability to conform the conduct to the requirements of the law.²⁹² Some states do not

562.

289. See, e.g., *People v. Holt*, 937 P.2d 213, 231 (Cal. 1997); *People v. Crittenden*, 885 P.2d 887, 901 (Cal. 1995) (en banc); see generally Appendix B, *supra* note 2.

290. *Skipper*, 476 U.S. at 4 (“[T]he sentencer may not refuse to consider or be precluded from considering ‘any relevant mitigating evidence.’” (quoting *Eddings v. Oklahoma*, 455 U.S. 104, 114 (1982))); see also Judith G. Edersheim et al., *Neuroimaging, Diminished Capacity and Mitigation*, in *NEUROIMAGING IN FORENSIC PSYCHIATRY* 163, 175 (Joseph R. Simpson ed., 2012).

291. A brain scan is not required in order for a defendant's organic brain damage to be considered a mitigating factor. See Edersheim et al., *supra* note 290. If a psychiatrist or psychologist is able to diagnose a defendant through traditional evaluation procedures and testify to the defendant's brain damage and mental deficiencies, the court can accept the expert testimony as establishing the defendant's neurological and cognitive impairments as well as brain damage. See *id.* The 2008 Florida case of *Owen v. State* is an example of a court making a finding of organic brain damage based on multiple experts' testimony regarding Owen's mental health. *Owen v. State*, 986 So. 2d 534, 552 (Fla. 2008) (per curiam). The organic brain damage was considered as one of 16 non-statutory mitigating circumstances and was assigned “some weight” by the trial court. *Id.* at 552 n.14. Despite the significant mitigating evidence (three statutory and 16 non-statutory mitigating factors), the court concluded it was not significant enough to outweigh the four aggravating factors, and Owen's death sentence for first-degree murder was upheld. *Id.* at 552.

292. Examples of states that have statutory mitigating factors are Alabama, Arkansas, California, Florida, Kansas, Louisiana, and Montana. See, e.g., ALA. CODE § 13A-5-51 (West 2016) (“Mitigating circumstances shall include, but not be limited to [seven listed factors]”); ARK. CODE ANN. § 5-4-605 (West 2016) (providing a list of six mitigating factors). In the event the defendant is unable to establish either of those statutory mitigating factors, an abnormal brain scan or other evidence of brain damage may still be considered a non-statutory mitigating factor. See *Johnston v. State*, 841 So. 2d 349, 353–54, 359–60, 360 & n.13 (Fla. 2002) (per curiam) (finding, by the trial court, that the evidence was not sufficient to support the statutory mitigating factor of extreme

provide statutory mitigating factors, and thus neuroimaging evidence of brain damage is considered as a non-statutory mitigating factor in those states—leaving the exact description and weight of it to be decided by the jury or trial court.²⁹³ As a practical matter, when that occurs, in this sample of cases where the defendant ultimately receives the death penalty, the presence of brain damage is typically given little weight.²⁹⁴

One of the reasons a defendant must be able to investigate mental health evidence, especially in death penalty cases, is because failure to do so may deny the defendant an opportunity not only to develop mitigating evidence, but also to rebut aggravating evidence.²⁹⁵ Mitigating mental health evidence can be very significant because weighty mitigating factors may be a defendant's only hope of avoiding the death penalty.

While the cases presented in this Article will not give this impression due to the sampling bias explained above, capital defendants can present mitigating evidence that outweighs the aggravating evidence, making the imposition of the death penalty unwarranted.²⁹⁶ In the 2005 case of *Crook v. State*,²⁹⁷ the Florida Supreme Court found just that—the death sentence was disproportionate punishment for first-degree murder in light of extreme mitigation.²⁹⁸ Donny Crook did not appeal his conviction or the aggravating factors found by the court but rather the outcome of the penalty phase, claiming his case “was one of the most mitigated.”²⁹⁹ Additionally, he argued “the trial court erred in failing to address and weigh his brain damage as

emotional disturbance but PET scan evidence and expert testimony were accepted as mitigating evidence).

293. See, e.g., GA. CODE ANN. § 17-10-30 (West 2016) (using a system that instructs the judge or jury to consider any mitigating circumstances authorized by law and to balance those against any aggravating circumstances authorized by law or any of the 11 statutory aggravating circumstances listed in the statute).

294. See, e.g., *Welch v. State*, 992 So. 2d 206, 210 (Fla. 2008) (per curiam) (admitting abnormal brain scan as a non-statutory mitigating factor with little weight).

295. See *id.* at 215 (discussing the low threshold for getting jury to consider aggravating factors).

296. One case that demonstrates the difficulty of outweighing aggravating factors with mitigating evidence is *Johnston*, 841 So. 2d at 360 (upholding death penalty after balancing four statutory aggravating factors, one statutory mitigating factor, and 26 non-statutory mitigating factors including the factor “the defendant tried to conform his behavior to normal, but has been thwarted by his mental illness and brain dysfunction,” which was given “slight weight”).

297. *Crook v. State*, 908 So. 2d 350 (Fla. 2005) (per curiam).

298. *Id.* at 358.

299. *Id.* at 352.

mitigation.”³⁰⁰ The Florida Supreme Court agreed and found “[m]ost persuasive” the unrefuted expert testimony that linked Crook’s impairments—including his organic brain damage and his substance abuse problem—to his functioning at the time of the murder.³⁰¹ Noting that while Crook’s mental deficiencies do not “rise to the level of insanity” that would preclude him from being convicted of the murder, nor mental retardation that would prohibit his execution, the “mental deficiencies [do] merit great consideration in evaluating [a] defendant’s culpability in a proportionality assessment.”³⁰²

The presence and severity of brain damage can be a critical factor in determining whether a death sentence is an appropriate punishment. In the case of *State v. Sireci*,³⁰³ the Florida Supreme Court granted a defendant a new sentencing hearing because he failed to receive competent psychiatric examinations that adequately investigated possible brain damage and mental retardation.³⁰⁴ Due process requires an adequate investigation into a defendant’s mental history when appropriate and, if justified, additional testing to assist in evaluating the defendant’s condition.³⁰⁵ Additional testing has come to encompass brain scans, and medical experts state with increasing frequency that such technology enables them to make a more complete and accurate assessment of the defendant’s neurological and psychological state.³⁰⁶

One hundred and seventy-one reported cases involved the attempted

300. *Id.*

301. *Id.* at 359.

302. *Id.* at 358.

303. *State v. Sireci*, 536 So. 2d 231 (Fla. 1988) (per curiam).

304. *Id.* at 232–33 (affirming an order granting a new penalty phase hearing because there was “substantial evidence that the defendant’s organic brain disorder existed at the time” of the offense and reasonable medical standards at the time warranted additional testing to investigate the presence of that organic brain disorder). The court was careful to point out that a finding of organic brain damage alone does not necessarily require a new sentencing hearing. *Id.* at 232. However, a new sentencing hearing is warranted when the psychiatric examinations conducted were so insufficient that they did not take into account mental retardation or organic brain damage when there was evidence to suggest those conditions may have been present. *Id.* (citing *Mason v. State*, 489 So. 2d 734, 736 (Fla. 1986)).

305. *Id.* at 233.

306. *See Hoskins v. State*, 702 So. 2d 202, 208 (Fla. 1997) (per curiam) (discussing testimony of a neuropsychologist that a PET scan would allow him to render a more detailed and definitive opinion about the neurological status of the defendant than he could with the data he had available).

use of neuroimaging results as mitigating evidence. These cases are described below under the following categories: (1) neuroimaging evidence introduced as mitigating evidence, but with the jury sentencing the defendant to death anyway; (2) defendant seeking brain scan for mitigation case; (3) admissibility of brain scan in the penalty phase; and (4) IAC claims somehow related to neuroimaging evidence.

1. *Admissible but Ineffective Mitigating Evidence*

Over the last ten years, evidence of brain damage and dysfunction has become increasingly common in the sentencing phase of capital cases. In the majority of the cases identified through Westlaw, evidence of defendants' brain abnormalities, damage, or dysfunction—established via various brain scan techniques and presented by expert testimony—was admitted during the penalty phase, but the defendant's death sentence was nonetheless upheld on appeal.³⁰⁷ Because these cases all involved a defendant who was convicted at trial and sentenced to death, the neuroimaging evidence had no

307. *Roberts v. Norris*, 526 F. Supp. 2d 926, 932, 949 (E.D. Ark. 2007); *People v. Parson*, 187 P.3d 1, 9, 29 (Cal. 2008); *People v. Danks*, 82 P.3d 1249, 1253, 1261, 1281 (Cal. 2004); *People v. Sapp*, 73 P.3d 433, 442, 469 (Cal. 2003); *People v. Yeoman*, 72 P.3d 1166, 1178, 1184–85 (Cal. 2003); *People v. Crittenden*, 885 P.2d 887, 895, 901 (Cal. 1995) (en banc); *Sexton v. State*, 997 So. 2d 1073, 1075, 1083–84, (Fla. 2008) (per curiam); *People v. Urdiales*, 871 N.E.2d 669, 674, 683–84 (Ill. 2007); *Gallego v. State*, 23 P.3d 227, 232 (Nev. 2001), *abrogated by* *Nunnery v. State*, 263 P.3d 235 (Nev. 2011) (en banc); *State v. Mercer*, 672 S.E.2d 556, 562–63 (S.C. 2009); *State v. Reid*, 213 S.W.3d 792, 804–05, 808 (Tenn. 2006). There were five cases where defendants appealed their sentences on the basis of various insufficiencies of medical and mental health testimony after neuroimaging had been conducted but the results were normal. *People v. Kraft*, 5 P.3d 68, 81, 98 (Cal. 2000) (admitting, as mitigating evidence, PET scan evidence that revealed abnormalities, but jury and trial court still sentenced defendant, known as the Southern California Strangler, to death); *People v. Holt*, 937 P.2d 213, 231 (Cal. 1997) (admitting, as mitigating evidence, PET scan and EEG results as evidence of organic brain dysfunction and temporal lobe epilepsy); *Welch v. State*, 992 So. 2d 206, 210, 217 (Fla. 2008) (per curiam) (stating only that defendant offered testimony of “mental mitigation experts” but not discussing experts’ conclusions); *Smithers v. State*, 826 So. 2d 916, 921–22 (Fla. 2002) (per curiam) (admitting defense expert’s testimony that defendant’s PET scan was “abnormal and consistent with brain damage due to head trauma,” while prosecution experts testified the PET scan images were insufficient to make a determination that defendant’s brain was not functioning properly). The fifth case worth mention is *Rogers v. State*, in which MRI scan results were admitted in the penalty phase but the scan revealed no evidence of brain damage. *Rogers v. State*, 783 So. 2d 980, 998 (Fla. 2001) (per curiam). Even though the MRI in *Rogers* was normal, defense experts still presented testimony regarding Rogers’s brain damage, psychotic disturbances, and other psychiatric evidence. *Id.* at 999.

significant impact, other than being admitted and considered as mitigating evidence.³⁰⁸ The neuroimaging evidence in these cases did not sway the jury's conclusion, which is not surprising given that most of cases involved violent crimes with very strong aggravating factors introduced in the penalty phase.³⁰⁹ Also, as noted above, if the neuroimaging evidence was successful in mitigating the sentence, the case would likely not have been appealed and, thus, would likely not result in a reported case that could be detected by our search methodology.³¹⁰

It should nevertheless be noted that in a few cases, the court suggested that neuroimaging evidence would be necessary or helpful to support a mitigating claim of organic brain damage. In the 1994 case of *State v. Scudder*, the Ohio Supreme Court found the defendant was unable to establish he suffered from organic brain damage because no MRI had been performed and the medical expert that diagnosed the brain damage did not perform any sophisticated psychological testing.³¹¹ However, in other cases, courts have found the mitigating factor of brain damage established without a corroborative brain scan, if a psychiatrist or psychologist was able to diagnose definitively a defendant through traditional evaluation procedures and testify to the defendant's brain damage and mental deficiencies, which was the case in *Cole v. State*,³¹² *Owen v. State*,³¹³ and *Hawk v. State*.³¹⁴

308. See cases cited *supra* note 307.

309. See cases cited *supra* note 307.

310. See *supra* Part III.

311. *State v. Scudder*, 643 N.E.2d 524, 534 (Ohio 1994).

312. *Cole v. State*, 164 P.3d 1089, 1102 (Okla. Crim. App. 2007) (affirming the trial court's sentence of death for a murder conviction after accepting defendant's brain damage as mitigating evidence but refusing to grant continuance for further development of MRI results). Cole had an MRI that allegedly revealed abnormalities but had failed to have an expert review the scan so it could be used as mitigating evidence. *Id.* at 1093. The court refused to grant Cole a continuance for an expert to review the scan because he had had ample time to do so, brain damage was considered a mitigating factor without the scan, and the death sentence was "factually substantiated and appropriate" in Cole's case. *Id.* at 1093, 1102.

313. *Owen v. State*, 986 So. 2d 534, 552 (Fla. 2008) (per curiam) (finding organic brain damage based on multiple experts' testimony regarding Owen's mental health). Owen's requests for post-conviction relief and habeas corpus were denied. *Id.* at 542, 560; see *supra* text accompanying note 291.

314. *Hawk v. State*, 718 So. 2d 159, 160 (Fla. 1998) (per curiam) (reversing the death sentence and imposing "a life sentence without the possibility of parole" for a first degree murder conviction), *abrogated by* *Connor v. State*, 803 So. 2d 598 (Fla. 2009) (per curiam). The court noted as important mitigating evidence the testimony of a forensic

Since neuroimaging technology is increasingly available and well-known among defense counsel, it is probable that such testing and results are becoming routine evidence in the sentencing phase of capital cases—especially in the states where the results of the scan can support statutory mitigating factors. In a number of recent decisions, courts considered brain scan evidence produced on behalf of the defendant even though the data did not reveal any brain damage, and the lack of findings ended up undercutting the mitigation claims of the defendant.³¹⁵

2. Defendant Seeks Brain Scan as Mitigating Evidence

In 23 cases, defendants sought a brain scan test they believed would reveal valuable mitigating evidence. In two of those cases, the defendant's request was granted.³¹⁶ Similar to the requests for testing in the guilt phase of a trial, a defendant must establish particularized need for the testing for the court to grant his or her request.³¹⁷ Particularized need is demonstrated when (1) a brain scan is necessary “for experts to make a more definitive determination as to whether [a] defendant's brain is functioning properly and to [formulate] their opinions about the extent of the defendant's brain damage,” and (2) when a defendant makes a showing that they were “prejudiced by the . . . denial of the motion requesting a scan.”³¹⁸

psychologist that the defendant had impairment from a brain injury (likely caused by meningitis). *Id.* at 162–63. The court found numerous non-statutory mitigating factors including brain damage. *Id.* at 163.

315. *Samra v. Warden*, 626 F. App'x 227, 241–42 (11th Cir. 2015) (per curiam), *cert. denied*, 136 S. Ct. 1668 (2016) (mem.); *Medina v. Chappell*, 781 F.3d 1076, 1086 (9th Cir. 2015), *vacated by* 782 F.3d 1115 (9th Cir. 2015) (mem.); *Sorto v. Stephens*, No. H-10-CV-613, 2015 WL 5734464, at *41 (S.D. Tex. Sept. 30, 2015), *appeal docketed*, No. 16-10005 (5th Cir. Feb. 16, 2016); *Apelt v. Ryan*, No. CV-98-00882-PHX-ROS, 2015 WL 5119670, at *23 (D. Ariz. Sept. 1, 2015), *reconsideration denied*, No. CV-98-00882-PHX-ROS, 2015 WL 7732670 (D. Ariz. Dec. 1, 2015); *Holiday v. Stephens*, No. H-11-1696, 2013 WL 3480384, at *37 (S.D. Tex. July 10, 2013), *certificate of appealability denied*, 587 F. App'x 767 (5th Cir. 2014).

316. *Hernandez-Alberto v. State*, 889 So. 2d 721, 731 (Fla. 2004) (per curiam) (granting defendant's first request and funds for a PET scan but denying a second request because the defendant refused to let the test be performed on him the first time around); *Hoskins v. State*, 702 So. 2d 202, 210 (Fla. 1997) (per curiam); *see also* Appendix A, *supra* note 2.

317. *Ferrell v. State*, 918 So. 2d 163, 176 (Fla. 2005) (per curiam).

318. *Id.* (affirming denial of a SPECT scan and finding defendant failed to establish particularized need required for a court to authorize a SPECT scan because the test would only have been helpful to a diagnosis of brain damage, and finding defendant failed to establish prejudice because the scan would not have provided new

Statements that a brain scan *could* be helpful are usually not sufficient to establish particularized need.³¹⁹ In three cases, the defendants had already had some type of brain scan test and requested additional testing.³²⁰ Two

information—only corroboration); *Robinson v. State*, 761 So. 2d 269, 275–77 (Fla. 1999) (per curiam) (finding that defendant failed to establish need for neurological testing to show he suffered from brain damage, trial court adequately considered and weighed mitigating evidence, and death penalty was proportionate). The court distinguished Robinson’s case from *Hoskins*, where an expert testified that an exam was necessary to the formation of his or her medical opinion, whereas for Robinson it would have merely been helpful. *Id.* at 275–76 (citing *Hoskins*, 702 So. 2d 202); *see also* *United States v. Phillips*, No. 89-5686, 1990 WL 92625, at *1 (6th Cir. Jul. 3, 1990) (per curiam) (denying request for a BEAM analysis, finding defendant failed to meet the burden of establishing what the BEAM analysis would add to his defense because defendant merely wanted the test to explore the potential effects of a gunshot wound to his face); *Allen v. Hickman*, 407 F. Supp. 2d 1098, 1099, 1105 (N.D. Cal. 2005) (denying a 75-year-old defendant’s request for SPECT or MRI testing in order to develop mitigating evidence in his clemency proceeding because a doctor’s affidavit did not suggest any signs of organic brain dysfunction and “there were no signs of neurobehavioral impairment” in defendant’s medical records); *Bottoson v. State*, 813 So. 2d 31, 34 (Fla. 2002) (per curiam) (denying defendant’s request for leave of court to obtain a PET or SPECT scan, and finding defendant failed both prongs of the tests); *Davis v. State*, 742 So. 2d 233, 237 (Fla. 1999) (per curiam) (affirming trial court’s denial of defendant’s request for a PET scan that was unsupported and therefore speculative, and finding defendant’s claim was meritless because there was no reasonable likelihood the outcome of the trial would have been different and the claim was procedurally barred because it could have been raised in an earlier post-conviction motion); *Woodall v. Commonwealth*, 63 S.W.3d 104, 126 (Ky. 2002) (finding no error in the trial court’s denial of defendant’s request for a continuance and funds to obtain a PET scan because defendant failed to establish the reasonable necessity required after the state psychiatric center’s medical evaluation of the defendant specifically ruled out the presence of brain damage).

319. *State v. Newton*, 840 N.E.2d 593, 609–10 (Ohio 2006) (finding no abuse of discretion to reject defendant’s request for funds for a PET scan because it “might provide ‘potentially’ useful information”); *State v. Trimble*, No. 2007-P-0098, 2008 WL 5147441, at *3 (Ohio Ct. App. Dec. 5, 2008) (explaining that a doctor’s affidavit stating that neuroimaging techniques, “such as a quantitative MRI and/or PET scan[,] could have been helpful in documenting abnormalities in [the defendant’s] brain structure and function” was insufficient to establish particularized need); *see also* *Rogers v. State*, 783 So. 2d 980, 998–99 (Fla. 2001) (per curiam) (submitting an expert affidavit that stated, “[u]pon consideration of my preliminary evaluation of Glen Rogers it is evident that a PET-Scan of the brain will be necessary to complete this evaluation,” but affirming trial court’s denial of the request for funding by explaining that the conclusory affidavit failed to establish a particularized showing of need for the PET scan).

320. *Noel v. Norris*, 322 F.3d 500, 503 (8th Cir. 2003); *Rogers*, 783 So. 2d at 998–1000; *Gallego v. State*, 23 P.3d 227, 242 (Nev. 2001) (en banc), *abrogated by* *Nunnery v. State*,

defendants claimed that the abnormal results of their first scan provided justification for additional tests to determine the extent of the damage,³²¹ while the other defendant claimed a “normal” first scan provided justification for additional tests since experts believed he had brain damage and having a jury see only a scan with normal results would be misleading.³²² In all of those cases, the trial courts were found to have acted within their discretion in denying the requests for additional scans.³²³

Hoskins v. State,³²⁴ a 2007 Florida case, is one of the two successful cases where the defendant’s request for a brain scan was granted on appeal.³²⁵

Box 5: *Hoskins v. State*

Defendant’s Request for Brain Scan Successful

The Crime: Hoskins lived with his girlfriend next door to 80-year-old Dorothy Berger.³²⁶ One evening, police went to Dorothy’s home because “her door was open but no one was home” and her vehicle was gone.³²⁷ Inside the house, police discovered “a small amount of blood, a bent pair of eyeglasses,” several items out of place, and a dusty shoe print.³²⁸ The night before police arrived, Hoskins was seen driving a car similar to Dorothy’s.³²⁹ He drove the car to his parents’ home, which was over six hours away, where he borrowed a shovel and abruptly left.³³⁰ On his return drive from his parents’ home, Hoskins was stopped for a traffic violation, and police determined the car belonged to Dorothy.³³¹ Blood and

263 P.3d 235 (Nev. 2011) (en banc).

321. *Noel*, 322 F.3d at 503; *Gallego*, 23 P.3d at 242.

322. *Rogers*, 783 So. 2d at 998.

323. *Noel*, 322 F.3d at 504; *Rogers*, 783 So. 2d at 999; *Gallego*, 23 P.3d at 369–70.

324. *Hoskins v. State*, 702 So. 2d 202 (Fla. 2007) (per curiam); *see infra* Box 5.

325. *Hoskins*, 702 So.2d at 210; *People v. Jones*, 620 N.Y.S.2d 656, 657–58 (App. Div. 1994), *aff’d* by 654 N.E.2d 1209 (N.Y. 1995).

326. *Hoskins*, 702 So. 2d at 203–04.

327. *Id.*

328. *Id.* at 204.

329. *Id.*

330. *Id.*

331. *Id.*

vegetation were found in the back of the car.³³² Hoskins's father recognized the vegetation and led police to the place near his home where it grew, where they found Dorothy's buried body.³³³ The autopsy revealed that Dorothy had been raped and beaten; one particular blow to her head likely knocked her unconscious.³³⁴ She died from manual strangulation after the rape and beating.³³⁵ "[S]emen found on the [body] and on [Dorothy's] bed sheet could have come from Hoskins."³³⁶

The Trial and Appeal: Hoskins was convicted of "first-degree murder, burglary of a dwelling, sexual battery with physical force, kidnapping, and robbery."³³⁷ The court sentenced him to death for the first-degree murder.³³⁸ Hoskins appealed his convictions and sentence; one of his arguments was that the trial judge improperly denied his request for a PET scan.³³⁹ The trial court had appointed Dr. Krop, a neuropsychologist, to assist with Hoskins's defense.³⁴⁰ Dr. Krop's neuropsychological testing indicated Hoskins might suffer from brain damage.³⁴¹ A PET scan would have allowed him to confirm the presence of brain damage and make a more thorough assessment of Hoskin's neurological status.³⁴² Dr. Krop testified that when a violent crime has been committed, it is relevant to know whether there is a neurological basis for poor impulse control, such as an abnormality in the frontal lobe—an area of the brain responsible for inhibition.³⁴³ Dr. Krop explained that while "PET scan is a relatively new examination[,] [it] is now recognized in the field of neuropsychology as a valid diagnostic tool."³⁴⁴ At the hearing on the motion to authorize the PET scan, Dr. Krop gave the following testimony:

Q. Well, Doctor, assuming that we won't dispute that he has brain damage, okay, the State never did dispute the existence of brain damage. My question is even assuming there is brain damage, is that going to change your answers with regard to the fact that you cannot say that there is a relationship between that brain damage and the specific behavior exhibited here?

A. That is probably true, unless I received additional information.³⁴⁵

The trial judge denied Hoskins's request for a PET scan, deciding it would merely confirm the presence of brain damage, which was not disputed by the State.³⁴⁶ Therefore, the trial court concluded the PET scan would not

add anything novel and was unnecessary.³⁴⁷

The Florida Supreme Court: The Florida Supreme Court disagreed with the lower court's decisions, believing Dr. Krop's testimony revealed that a PET scan was necessary for him to render a complete medical opinion regarding Hoskins's mental condition.³⁴⁸ Consequently, the supreme court found the trial court abused its discretion when it denied the request for testing that was required for a complete evaluation of Hoskins.³⁴⁹ The error of the trial court was worsened when the judge expressed that Hoskins's mental condition was not at issue because Dr. Krop had not made Hoskins's mental state "relevant"; the supreme court pointed out that the mitigating circumstances set forth in the statute reveal that a defendant's mental condition is a major element to be considered in a penalty phase proceeding and thus is always relevant.³⁵⁰ Without the results of the neurological tests, the court could not say whether the error of the trial court had an impact on the outcome.³⁵¹ The court affirmed the convictions and the sentences other than the death sentence and remanded the case so a neurological test could be conducted.³⁵² The

332. *Id.*

333. *Id.*

334. *Id.*

335. *Id.*

336. *Id.*

337. *Id.* at 203.

338. *Id.*

339. *Id.* at 204–205, 208.

340. *Id.* at 209.

341. *Id.* at 208.

342. *Id.*

343. *Id.*

344. *Id.* at 209 n.5.

345. *Id.* at 213 (Grimes, J., dissenting).

346. *Id.* at 209 (majority opinion).

347. *See id.*

348. *Id.*

349. *Id.*

350. *Id.* at 209–10.

351. *Id.*

352. *Id.* at 210.

results of the test would determine whether a new penalty phase hearing was warranted.³⁵³ The purpose of remand was to determine whether a PET scan of Hoskins' brain revealed abnormalities and whether Dr. Krop's testimony would have changed once he had the scan results.³⁵⁴ The trial judge on remand would determine only whether Dr. Krop's testimony would change because of the PET scan results, and if so, a new penalty phase proceeding was warranted.³⁵⁵

The Neuroimaging Evidence: As it turned out, the PET scan revealed an abnormality and Dr. Krop's testimony changed as a result.³⁵⁶ The case was then remanded for a new penalty phase hearing during which the validity of the PET scan and *Frye* issues would be addressed.³⁵⁷ The *Frye* hearing resulted in the PET scan evidence being admitted, despite the State's objections.³⁵⁸ The court declined to find the statutory mitigating factor of extreme emotional disturbance even though Hoskins suffered from a "hypofrontal lobe abnormality [which] can result in reduced ability to control impulsive behavior" because it is not the same thing as a mental or emotional disturbance.³⁵⁹ The trial court found that the testimony was clear that "there was no connection between the frontal lobe impairment and Hoskins's . . . actions" at the time of the murder.³⁶⁰ Dr. Krop testified that Hoskin's actions were consistent with someone who knew he had done something wrong and was trying to hide it and avoid being caught.³⁶¹ The court also declined to find the statutory mitigating factor that Hoskins failed to appreciate the criminality of his conduct at the time of the murder as a result of a frontal lobe impairment.³⁶² Hoskins sexually assaulted Dorothy in her home, bound and gagged her, and placed her body in the trunk.³⁶³ Hoskins's purposeful actions of driving to a remote area, stopping

353. *Id.*

354. *Id.*

355. *Id.*

356. *Hoskins v. State*, 735 So. 2d 1281, 1281 (Fla. 1999) (per curiam).

357. *Id.* at 1281 & n.1.

358. *Hoskins v. State*, 965 So. 2d 1, 6 (Fla. 2007) (per curiam).

359. *Id.* at 17.

360. *Id.*

361. *Id.* at 18.

362. *Id.*

363. *Id.*

to borrow a shovel, and then continuing to a deserted area where he killed her and buried her body suggested Hoskins was acting deliberately and in complete control.³⁶⁴ When Hoskins's brother inquired about blood that was dripping from the wheel well of the car, Hoskins told him he had hit a possum.³⁶⁵ The court found that Hoskins's actions were purposeful and meant to avoid detection.³⁶⁶

The Result: "The jury recommended death by a vote of 11-1," finding three statutory aggravating factors and one statutory and 15 nonstatutory mitigating factors, all given little weight, one of which was that Hoskins had "some abnormalities in the brain which may cause some impairment."³⁶⁷ Concluding any one of the aggravating factors outweighed the mitigating factors, Hoskins was again sentenced to death, and the sentence was affirmed by the Florida Supreme Court.³⁶⁸

3. Admissibility of Brain Scan in Penalty Phase

As a result of the due-process-oriented framework, and because the consequence of error is so great, the standards for admissibility of evidence in the penalty phase are much more lax than in other phases of the trial.³⁶⁹ In *Bible v. Schiro*,³⁷⁰ a 2007 Arizona case, the federal district court recognized, "if Petitioner had presented the trial court with evidence that he suffered from some type of neurological impairment, the court would have been obligated to consider such information, whether or not Petitioner could establish a connection between the condition and his crimes."³⁷¹ Thus, the link between the brain scan and behavior that the courts look for in the guilt phase is not needed for neuroimaging evidence and mental health testimony

364. *Id.*

365. *Id.*

366. *Id.*

367. *Id.* at 6, 22.

368. *Id.* at 22.

369. *Hoskins v. State*, 702 So. 2d 202, 209 (Fla. 1997) (per curiam) (citing *Ake v. Oklahoma*, 470 U.S. 68 (1985)).

370. *Bible v. Schiro*, 497 F. Supp. 2d 991 (D. Ariz. 2007), *aff'd by Bible v. Ryan*, 571 F.3d 860 (9th Cir. 2009).

371. *Id.* at 1060 n.52 (citation omitted).

to be admitted in the penalty phase.³⁷² As long as a defendant is able to provide evidence of any condition, physical or mental, a court is obligated to hear it as mitigating evidence, regardless of whether a defendant can establish a connection between the condition and the crime.³⁷³

Appellate and state supreme courts will not overturn a trial court's admission or exclusion of evidence absent an abuse of discretion.³⁷⁴ "An abuse of discretion [exists] when the trial court's ruling is based on an error of law."³⁷⁵ Appellate courts that have found a trial court erred in excluding brain scan and other neurological evidence may conclude the error does not warrant reversal because no prejudice had been shown or because the evidence would have had minimal mitigating value if it had been admitted, and therefore would not have affected the sentence.³⁷⁶

Timing can also be an issue when it comes to a defendant seeking to admit mitigating neuroimaging evidence, as a court can determine too much time has passed between the crime and the tests so that any damage or impairment reflected in the test cannot retroactively be presumed to have existed at the time of the crime.³⁷⁷ In two cases, defendants tried to argue

372. *Id.* While a direct link between the brain scan and behavior is not required in the penalty phase, in order to have value as mitigating evidence, brain abnormalities need to be linked to some sort of impairment in intellectual or cognitive functioning. *Id.* In other words, the brain damage must be linked to a deficit of some sort. *See id.*

373. *Id.*

374. *People v. Rodriguez*, 971 P.2d 618, 622 (Cal. 1999) (compiling cases); *San Martin v. State*, 705 So. 2d 1337, 1347 (Fla. 1997) (per curiam) ("A trial court's refusal to provide funds for the appointment of experts for an indigent defendant will not be disturbed unless there has been an abuse of discretion."). For example, the Florida Supreme Court uses a two-part abuse of discretion standard. *Rogers v. State*, 783 So. 2d 980, 999 (Fla. 2001) (per curiam); *Robinson v. State*, 761 So. 2d 269, 275–76 (Fla. 1999) (per curiam). First, the defendant must show particularized need, and second, the defendant needs to establish prejudice as a result of the denial of the motion to obtain a scan. *Rogers*, 783 So. 2d at 999; *Robinson*, 761 So. 2d at 275–76.

375. *State v. Washington*, 665 S.E.2d 602, 604 (S.C. 2008) (citation omitted).

376. *E.g.*, *Zink v. State*, 278 S.W.3d 170, 182 (Mo. 2009) (en banc) (finding no reasonable probability that a jury would have returned a sentence other than death had the PET scan evidence been admitted in the penalty phase). First, the PET scan likely had minimal mitigating value because "there [wa]s no generally accepted scientific link between Mr. Zink's brain abnormalities and his diagnosed personality disorders." *Id.* Second, Mr. Zink possessed above average cognitive abilities, and there was no evidence those abilities were impaired. *Id.*

377. *See Noel v. Norris*, 322 F.3d 500, 503 (8th Cir. 2003) (rejecting claim for further brain scan testing after defendant presented a SPECT scan that revealed abnormalities; defendant wanted to develop mitigating evidence of brain damage years after he had

that neuroimaging evidence constituted newly discovered evidence warranting post-conviction relief; in one case the defendant sought a new trial, and in both cases the court denied the defendants' requests.³⁷⁸

It has been argued that the prejudicial effect of neuroimaging evidence outweighs its probative value and therefore should not be admitted into criminal trials even in the sentencing phase because it fails the balancing test of Federal Rule of Evidence 403.³⁷⁹ A trial court in South Carolina adopted that view and excluded testimony of an expert witness in the penalty phase regarding a defendant's SPECT scan results that showed an abnormality and other relevant psychiatric information because the probative value of his testimony was deemed to be substantially outweighed by the danger of unfair prejudice to the State.³⁸⁰ The South Carolina Supreme Court disagreed with the ruling, finding that the expert's testimony was improperly excluded, yet in the end, the court decided it was harmless error.³⁸¹ The court found the exclusion to be harmless error because a doctor had already testified to defendant's cognitive deficiencies, and the abnormal brain scan

already been sentenced to death and the court explained there is no constitutional right to resentencing based on newly discovered mitigating evidence); *Ex parte Jennings*, Nos. AP-75806, AP-75807, 2008 WL 5049911, at *3, *6 (Tex. Crim. App. Nov. 26, 2008) (rejecting EEG and SPECT scans conducted eight years after the trial that indicated frontal and temporal lobe impairment but that could not establish the defendant's brain functioning at the time of the crime, and determining that even if defense counsel was found ineffective and the brain damage mitigation evidence allowed, there was so little other mitigation evidence that the defendant would not have received a life sentence rather than the death penalty).

378. *Taylor v. State*, 3 So. 3d 986, 998–99 (Fla. 2009) (per curiam) (denying request for retrial and finding results of a PET scan did not constitute newly discovered evidence warranting post-conviction relief because the scan did not reveal significant brain damage, defendant did not show scan would have been admissible at trial, and the sentencing court did consider proof of brain damage as mitigating evidence in the penalty phase); *Miller v. State*, 926 So. 2d 1243, 1259 (Fla. 2006) (per curiam) (finding PET scan did not constitute evidence of such a nature that it would probably produce an acquittal on retrial, as the PET scan results would have merely corroborated psychologist's testimony, and therefore defendant was not entitled to reconsideration of proportionality of his death sentence based on newly discovered evidence).

379. See generally Walter Sinnott-Armstrong et al., *Brain Images as Legal Evidence*, 5 EPISTEME: J. SOC. EPISTEMOLOGY 359 *passim* (2008).

380. *State v. Mercer*, 672 S.E.2d 556, 562 (S.C. 2009).

381. *Id.* at 562–63. An error will be deemed harmless if it “could not reasonably have affected the outcome of a trial.” *Id.* at 563 (citing *State v. Mitchell*, 336 S.E.2d 150, 151 (S.C. 1985) (quoting *State v. Key*, 180 S.E.2d 888, 890 (S.C. 1971))).

was admitted into evidence without objection from the State.³⁸²

4. *Claims of Ineffective Assistance of Counsel in the Penalty Phase*

Rompilla v. Beard is the leading case on ineffective assistance of counsel (IAC) as it relates to the investigation and presentation of mitigating evidence.³⁸³ In *Rompilla*, the U.S. Supreme Court held that defense counsel's failure to investigate mitigating evidence was deficient and below prevailing professional norms and resulted in prejudice to the defendant.³⁸⁴ The Supreme Court granted habeas relief on grounds of IAC.³⁸⁵ One of the things that a diligent defense counsel would have uncovered is that Rompilla had organic brain damage and significantly impaired cognitive function.³⁸⁶ That information, in combination with other aspects of Rompilla's childhood, family history, and mental state, had a great deal of potential as mitigating evidence.³⁸⁷ The Court decided Rompilla was prejudiced by this failure because there was a reasonable probability that if the mitigating evidence had been presented in its totality, the jury's assessment of Rompilla's culpability could have been different, thereby undermining the Court's confidence in the outcome.³⁸⁸ The failure to present the mitigating evidence was sufficient to undermine confidence that the jury would have still sentenced Rompilla to death had they heard this evidence.³⁸⁹ After

382. *Id.* at 562.

Dr. Donna Schwartz-Watts, a defense psychiatrist, testified that she "ordered what's called a SPECT Scan[—]one of the newer tests in medicine[—]and it shows brain function But what it does, it's a . . . picture of how your brain functions, and that test came back abnormal. There's a . . . small area that's not normal on there" Later, as Dr. Schwartz-Watts began to sum up her testimony, she again talked about the SPECT Scan. Referring to Mercer, she said that "it's already a bad brain in the sense that he's got a learning disability and . . . we even know that on a SPECT Scan there's an abnormality." Thus, the very "SPECT Scan abnormality" testimony Mercer sought to admit through Dr. Steedman was presented to the jury without objection through Dr. Schwartz-Watts.

Id. at 562–63.

383. *See generally* *Rompilla v. Beard*, 545 U.S. 374 (2005).

384. *Id.* at 390.

385. *Id.* at 379–80, 393.

386. *Id.* at 390–91.

387. *Id.* at 390–92.

388. *Id.* at 393.

389. *Id.* The Supreme Court reasoned that a certain amount of mitigating

Rompilla, the elements of an IAC claim will be satisfied if defense counsel fails to perform any meaningful investigation of defendant's background or hire anyone to investigate potential mitigating evidence when such an investigation, if conducted, would have revealed significant mitigating evidence.³⁹⁰

Notwithstanding *Rompilla*, forgoing neuroimaging of a defendant even if the scan might reveal organic brain damage and choosing instead to present mitigation testimony through lay witnesses has been held to be a reasonable trial strategy.³⁹¹ Conversely, focusing on organic brain damage in the penalty phase rather than relying on lay witnesses has also been held to be a reasonable strategy.³⁹² If a court believes neuroimaging evidence would have been cumulative with other mental health mitigation evidence, the court will not find an IAC claim for failure to pursue testing or failure to present the results of conducted tests.³⁹³ An IAC claim for failure to present

evidence can be sufficient to undermine confidence in the outcome when the defendant has been sentenced to death. *Id.* This reasoning presupposes that a jury would consider such mitigating evidence as making the defendant worthy of leniency and consequently recommend a life sentence rather than the death penalty. *See id.* In *Rompilla*, there were three aggravating factors, but the Supreme Court still thought it was possible that the mitigating evidence could overcome the aggravating evidence and result in a sentence less than death. *Id.* at 378, 393. Yet there are cases that suggest no amount of mitigating evidence will overcome one or more aggravating factors in a jury's eyes because defendants that have presented extensive mitigating evidence to the jury were still sentenced to death rather than life in prison. *Owen v. State*, 986 So. 2d 534, 552 (Fla. 2008) (per curiam) (concluding that even though the defendant "had one of the more horrific childhoods that this [c]ourt has seen or heard of," the substantial mitigating evidence "did not outweigh the four established aggravating factors"); *State v. Reid*, 213 S.W.3d 792, 820, 821–22 (Tenn. 2006) (affirming three first-degree murder convictions and death sentence, while noting the mitigating evidence was "compelling" but the aggravating circumstances "simply overwhelming").

390. *See Rompilla*, 545 U.S. at 383–89.

391. *Evans v. State*, 995 So. 2d 933, 949 (Fla. 2008) (per curiam).

392. *See Sexton v. State*, 997 So. 2d 1073, 1083–84 (Fla. 2008) (per curiam) (discussing penalty phase counsel's strategic decision to focus on the PET scan and demonstrable brain damage instead of other potentially prejudicial psychiatric testimony).

393. *Miller v. State*, 926 So. 2d 1243, 1252, 1259 (Fla. 2006) (per curiam) (denying defendant's IAC claim for failure to introduce PET scan data in penalty phase by explaining that a medical expert was allowed to testify to defendant's frontal lobe deficiency at trial and that the PET scan merely supported his initial conclusion of frontal lobe deficiency, making the PET scan data cumulative); *Forrest v. State*, 290 S.W.3d 704, 709 (Mo. 2009) (en banc) (denying IAC claim for failure to obtain a brain scan or present

evidence can also fail if the claim is barred by res judicata.³⁹⁴ And if there is no behavioral indication or nothing in the record that would prompt diligent counsel to raise the possibility that the defendant may have brain damage, counsel will not be found ineffective for failing to conduct brain scans.³⁹⁵ Lastly, if a defendant has an imaging evaluation and the results are normal, that essentially removes any duty of counsel to pursue additional testing.³⁹⁶

Further, refraining from having experts testify about neuroimaging evidence and potential brain damage if the testimony could act as a “double-edged sword” and has potential to be more aggravating than mitigating, or could open the door to potentially damaging evidence and testimony, has been deemed a reasonable trial strategy.³⁹⁷ This is particularly true if expert witnesses disagree as to the results of the brain scans and what the results mean.³⁹⁸ Consequently, it can be reasonable trial strategy for defense

testimony that would have been cumulative).

394. *Shank v. Mitchell*, No. 2:00-CV-17, 2008 WL 4449567, at *36 (S.D. Ohio Sept. 30, 2008) (finding no IAC claim for failure to present additional evidence regarding Scudder’s organic brain impairment properly denied by trial court under res judicata), *habeas corpus petition after State v. Scudder*, 643 N.E.2d 524 (Ohio 1994); *State v. Elmore*, No. 2005-CA-32, 2005 WL 2981797, at *16 (Ohio Ct. App. Nov. 3, 2005) (agreeing with trial court’s finding that defendant’s claim was barred by res judicata when defendant argued IAC for failing to secure funds for and arrange a PET scan that would show the extent of traumatic brain damage caused by an injury he suffered at the age of 16).

395. *Crawford v. Epps*, No. 3:04CV59-SA, 2008 WL 4419347, at *48, *50 (N.D. Miss. Sept. 25, 2008) (holding no IAC for failure to reveal at trial that defendant might have organic brain damage when an EEG of defendant’s brain was normal and there was no evidence to support the conclusion that any brain damage existed), *vacated in part by* 353 F. App’x 977 (5th Cir. 2009) (per curiam); *Jackson v. Norris*, 468 F. Supp. 2d 1030, 1042 (E.D. Ark. 2007) (rejecting IAC claim by explaining there was nothing in the record that warranted further investigation by trial counsel because defendant was evaluated by a forensic evaluation team and merely made a conclusory argument that *if* scans had been performed, organic deficits *might* have been revealed, but had not shown that the test results would have been mitigating evidence), *vacated by* 256 F. App’x 12 (8th Cir. 2007) (per curiam).

396. *See Epps*, No. 3:04CV59-SA, 2008 WL 4419347, at *50.

397. *Bible v. Schriro*, 497 F. Supp. 2d 991, 1059–60 (D. Ariz. 2007) (holding no IAC for not pursuing brain scans of defendant because counsel’s trial strategy was sound, and stating courts recognize the potential for mental health evidence [to act as] a ‘double-edged sword,’ particularly when counsel focuses his mitigation argument on the defendant’s character or amenability to rehabilitation”), *aff’d by Bible v. Ryan*, 571 F.3d 860 (9th Cir. 2009).

398. *See, e.g., Bonin v. Calderon*, 59 F.3d 815, 834 (9th Cir. 1995) (finding it was reasonable for defendant’s attorney to focus on an “institutional adjustment” theory as

attorneys to refrain from presenting equivocal evidence and expert testimony that may have minimal or no effect on their clients' cases, or may potentially hurt their clients' cases rather than help them.³⁹⁹ Neuroimaging evidence and testimony, just like other mental health testimony, can be sensitive and susceptible to numerous interpretations and in theory—data suggests this is the case very rarely—be a double-edged sword that reinforces the violent character of the defendant to the jury.⁴⁰⁰ Thus, it is within the province of defense counsel to refrain from putting an expert on the stand if he or she reasonably believes more damage than good could ultimately come of the expert's testimony.

Of the 97 IAC cases involving brain scan evidence at the sentencing phase, the defendant was successful in two cases⁴⁰¹ and courts remanded two other cases before reaching the IAC claims.⁴⁰² One of the successful claims was the 2013 appeal of *United States v. Witt* where the IAC claim was based on failure to investigate and develop mitigating evidence from a motorcycle accident.⁴⁰³ A mitigation specialist recommended brain imaging, but counsel did not pursue it.⁴⁰⁴ A CT scan after the accident was normal, but an expert said it was too soon after the accident to be reliable for the defense's purposes.⁴⁰⁵ The court agreed that defense counsel was deficient for not pursuing brain scanning because there was no other mitigating evidence and evidence of brain injury could have influenced the jury's decision.⁴⁰⁶ In the second successful claim from an appeal of a death sentence, the court found defense counsel's performance to be below prevailing professional norms because he did not investigate the defendant's background or any potential

mitigating evidence in the absence of "objective" evidence of brain disorder because defense and prosecution experts disagreed as to whether defendant's MRI and EEG revealed any abnormalities, and defendant's medical records did not reveal any neurological disorder so defense counsel did not want to give the State the opportunity to cross-examine expert witnesses regarding the details of each of the horrific murders).

399. *Id.*

400. *See id.*; *see also Bible*, 497 F. Supp. 2d at 1059–60; Denno, *supra* note 13.

401. *United States v. Witt*, 72 M.J. 727, 758, 766 (A.F. Ct. Crim. App. 2013), *aff'd on reconsideration*, 73 M.J. 738 (A.F. Ct. Crim. App. 2014) (en banc); *People v. Morgan*, 719 N.E.2d 681, 707–08 (Ill. 1999).

402. *People v. Nelson*, 922 N.E.2d 1056, 1071–72, 1092 (Ill. 2009); *People v. West*, 719 N.E.2d 664, 669, 681 (Ill. 1999).

403. *Witt*, 72 M.J. at 765–66.

404. *Id.* at 759.

405. *Id.* at 760, 766.

406. *Id.* at 766. The government appealed this finding. *Witt*, 73 M.J. at 753.

mitigating evidence, despite prompting from family members that such evidence likely existed.⁴⁰⁷ Had he investigated, he could have discovered that: (1) the defendant's brain damage, characterized as severe bilateral dysfunction to his frontal lobes, "was the determining factor in his behavior"; (2) if the defendant did not have brain damage he would have been able to "check" his impulses; (3) at the time of the crime the defendant's brain damage was "exacerbated by the effects of cocaine, PCP, and alcohol," placing him "under extreme emotional disturbance"; and (4) the defendant was acting in a paranoid or psychotic state, unable to think clearly, unable to plan, and excessively confused at the time of the crime.⁴⁰⁸ The court found counsel's failure to investigate and present the mitigating evidence relating to the defendant's organic brain damage was deficient and prejudicial, agreeing with the defendant's contention that inclusion of this evidence in the penalty phase could have likely resulted in the jury recommending a sentence other than death.⁴⁰⁹

The Tennessee Supreme Court used its 2014 opinion in *Davidson v. State* as an opportunity to "clarify the standards that capital defense attorneys must meet in order to provide effective representation at sentencing."⁴¹⁰ In *Davidson*, the defendant argued IAC in the penalty phase for failure to share relevant evidence with the defense neuropsychologist.⁴¹¹ This evidence included a CT that showed atrophy and an abnormal EEG.⁴¹² Interestingly, the court also rejected the claim that the evidence in question may have served as a double-edged sword.⁴¹³ The court upheld the defendant's conviction but vacated his death sentence and remanded the case to trial court for a new sentencing hearing.⁴¹⁴

407. *People v. Morgan* 719 N.E.2d 681, 707–08 (Ill. 1999). Decisions made by trial counsel after limited investigation can be reasonable but only if reasonable professional judgments support the limitations on investigation. *Wiggins v. Smith*, 539 U.S. 510, 521–22 (2003) (quoting *Strickland v. Washington*, 466 U.S. 668, 690–91 (1984)). In *Morgan*, as in *Wiggins*, reasonable professional judgments did not support the limited investigation. *Compare Wiggins*, 539 U.S. at 523–33, *with Morgan*, 719 N.E.2d at 707–08.

408. *Morgan*, 719 N.E.2d at 693, 710. If counsel had done his due diligence, he would have found an affidavit submitted by Dr. Jonathan Pincus, former chairman of the neurology department at Georgetown University, which listed the above conclusions. *Id.*

409. *Id.* at 707–08.

410. *Davidson v. State*, 453 S.W.3d 386, 392 (Tenn. 2014), *cert. denied*, 135 S. Ct. 1897 (2015).

411. *Id.* at 391–92, 395–96.

412. *Id.* at 396.

413. *Id.* at 405.

414. *Id.* at 406.

The records that defense counsel possessed pre-trial (including the CT and EEG reports from MTMHI) raised clear red flags that Mr. Davidson's mental functioning and social capabilities were quite impaired. Counsel's failure to develop this line of evidence does not strike us as a reasonable determination that further investigation would have been fruitless. The problem, rather, was inattention and a disturbing lack of time and resources Because mental illness can render a defendant less morally blameworthy, capital defense attorneys who possess compelling evidence of mental defects have an obligation to make a reasonable and fully-informed decision about presenting that evidence to the jury. Counsel's decision in this case was less than reasonable and fully-informed.

We are likewise not persuaded by the State's argument that opening the door to Mr. Davidson's mental health records would be a two-edged sword that hurt Mr. Davidson at sentencing more than it helped.⁴¹⁵

This case highlights the fact that counsel is obligated to do a full and thorough investigation into a defendant's mental health—and neuroimaging techniques are a tool that should often be used in that investigation.⁴¹⁶ When the data collected by the tools reveals compromise in brain structure and function, it is helpful information that can aid in counsel's and expert's understanding of the client and impairments that he or she may have. That data may also be consistent with and therefore provide support for a larger claim or claims that the client has brain damage or a neurodevelopmental condition or mental illness, and that construct then may have significant mitigating value.

The collection of cases discussed herein demonstrate two main categories of “proof” courts look for in order for a defendant to establish brain damage as it relates to IAC claims and as persuasive evidence that should have been considered in the penalty phase: expert testimony of brain damage or independent neuroimaging evidence. Some courts believe expert testimony that damage exists is sufficient proof.⁴¹⁷ Some look to independent neuroimaging evidence in conjunction with expert testimony—as was desired by the dissent in the 2014 opinion of *Forrest v. Steele*, discussed

415. *Id.* at 404–05.

416. *See id.* at 394–95 (emphasizing and discussing the importance of mitigation evidence in capital sentencing trials).

417. *See, e.g.,* *People v. Morgan*, 719 N.E.2d 681, 707–08 (Ill. 1999).

below.⁴¹⁸ And at least one court, as demonstrated by the 2014 opinion in *United States v. Witt*, also summarized below, has desired proof of a connection between a defendant's brain damage and behavior at the time of the crime, posing at least the possibility of a third category.⁴¹⁹

a. "*Objective*" evidence of brain damage desired. In the 2014 opinion in *Forrest v. Steele*,⁴²⁰ the Eighth Circuit Court of Appeals declined to find defense counsel ineffective for failing to obtain neuroimaging data to investigate the client's potential brain damage.⁴²¹ After considerable discussion of defense counsel's reasons for not obtaining neuroimaging data, the court found the decision to be "considered and strategic" and therefore not the type of uninformed decision that supports an IAC claim.⁴²² One of the reasons that trial counsel did not collect data is because the court rules in Missouri prevented motions for transport and testing of a capital defendant from being "*ex parte* and under seal," which allowed the prosecution to learn easily of negative results.⁴²³ The defense attorney in this case testified that if such testing *could* have been done *ex parte* and under seal, she "one hundred percent for sure" would have collected the imaging data.⁴²⁴

This opinion is interesting because a dissenting judge believed that trial counsel should have been found ineffective for not collecting imaging data—despite the reasons trial counsel offered in support of her decision.⁴²⁵ This judge prefaced his dissent with the statement: "We [the Eighth Circuit Court of Appeals] do not, and should not, require all defense counsel presenting evidence of brain damage to obtain a PET scan of their client."⁴²⁶ But then he explained that "this case presents an abnormal circumstance" where defense counsel's strategy focused almost exclusively on establishing the defendant had brain damage, yet counsel "failed to obtain any objective evidence" regarding that damage.⁴²⁷ This judge also explicitly rejected the Missouri Supreme Court's decision that any neuroimaging evidence would

418. See, e.g., *Forrest v. Steele*, 764 F.3d 848, 862–64 (8th Cir. 2014).

419. *United States v. Witt*, 73 M.J. 738, 775–76 (A.F. Ct. Crim. App. 2014) (en banc).

420. *Steele*, 764 F.3d at 848.

421. *Id.* at 855–56.

422. *Id.*

423. *Id.* at 854.

424. *Id.*

425. *Id.* at 862–64 (Bye, J., dissenting).

426. *Id.* at 863.

427. *Id.*

merely have been cumulative and argued that even though it could have been cumulative as to the “brain damage testified to *by the experts*, it would not have been cumulative” *for the jury*.⁴²⁸ Such data “would have played a separate, unique rol[e] in the penalty phase by providing objective evidence on which *the jury* could have relied to find [the defendant] had incurred brain damage.”⁴²⁹ In further supporting his dissent, the judge explained that defense experts had recommended the defendant undergo neuroimaging data collection.⁴³⁰

The majority believes trial counsels’ decision to forego a brain scan was “considered and strategic.” I disagree. I believe the Supreme Court of Missouri made an unreasonable determination of the facts because the court failed to take into account that the testimony of defense experts was undermined by a lack of medical evidence.

The center of the defense strategy at trial was to show [the defendant] should not be sentenced to death because he suffered from brain damage. The defense called several experts to testify about [the defendant]’s impaired functioning due to substance abuse, brain damage to [the defendant]’s right frontal lobe, [the defendant]’s impaired judgment and impulse control, and other cognitive disorders. During its cross-examination of defense experts and in closing arguments, the state effectively attacked the experts’ findings of [the defendant]’s brain damage by emphasizing there were no medical records or medical tests presented to corroborate the subjective opinions of these experts. The state repeatedly argued to the jury [the defendant] had failed to prove brain damage because the defense did not retain a physician to scan [the defendant]’s brain to demonstrate the brain damage existed with objective scientific evidence.⁴³¹

The State in fact took advantage of the lack of “objective scientific evidence” and asked one of the defense experts on cross-examination:

“Is there a single objective feature which you can show us, an MRI, an x-ray, anything where you can point to something and say here is this brain damage, or here is this problem with his brain?” The defense expert was required to acknowledge no brain scans had been

428. *Id.* (emphasis added).

429. *Id.* (emphasis added).

430. *Id.*

431. *Id.* at 862.

undertaken to corroborate the findings of brain damage. . . . The state's strategy was effective—the jury foreman later told a newspaper the jury did not believe [the defendant] had brain damage based on the evidence presented.⁴³²

The dissenting opinion in the Eighth Circuit represents the real role that neuroimaging can play in capital cases. If the right type of neuroimaging data is recommended, properly collected, and analyzed, it can provide the important objective evidence of brain damage that the dissenting judge referred to.⁴³³ When that objective evidence is then presented through expert testimony placing the findings (e.g., brain damage) in context and explaining its consequences and significance, it may be considered compelling evidence in favor of a life sentence.

Forrest also raises the important point that there are practical considerations—beyond expert recommendations—that trial attorneys must navigate in determining whether or not to pursue neuroimaging data collection.⁴³⁴ States that allow such testing of a defendant to be done *ex parte* provide the protection to defense counsel (and therefore the defendant) that encourages compliance with the ABA's recommendations.⁴³⁵ Specifically, such rules make it much more likely that defense counsel will follow through with mental health expert recommendations and pursue scanning since it is much less likely that any negative results will be used against their client.

b. Evidence connecting brain damage to behavior desired. In 2005, Air Force airman Andrew Witt was convicted of two counts of premeditated murder and one count of attempted premeditated murder and sentenced to death.⁴³⁶ His appeal “raised 88 issues . . . relat[ing] to the findings of guilt, the sentence, post-trial processing, and other miscellaneous systemic errors.”⁴³⁷ In 2013, the United States Air Force Court of Criminal Appeals affirmed the findings but not the sentence, granting defendant Witt's IAC claim for failing to investigate and develop mitigating evidence from a motorcycle accident a few months prior to the crime.⁴³⁸ A mitigation specialist had recommended

432. *Id.*

433. *See id.*

434. *See supra* notes 431–32 and accompanying text.

435. *See supra* notes 5, 431–32 and accompanying text.

436. *United States v. Witt*, 72 M.J. 727, 736 (A.F. Ct. Crim. App. 2013), *aff'd on reconsideration*, 73 M.J. 738 (A.F. Ct. Crim. App. 2014) (en banc).

437. *Id.*

438. *Id.* at 736, 758–61.

neuroimaging, but trial counsel did not pursue it.⁴³⁹ The court explained that defense counsel did not have much other mitigating evidence, and evidence of a brain injury could have influenced the jury's decision, leading the court to remand the case.⁴⁴⁰ The court found, "[H]ad the [jurors] been confronted with this additional mitigating evidence, there is a reasonable likelihood that at least one member would have struck a different balance between the aggravating and mitigating factors and would have returned with a different sentence."⁴⁴¹

The government then appealed the 2013 ruling.⁴⁴² In July 2014, the court reversed the earlier ruling as to the defendant's brain injury claim because there was not enough evidence that his injury had an effect on his behavior at the time of the murders, thus making the second prong—a showing of prejudice—unlikely.⁴⁴³

[W]e agree that a panel member could find a TBI mitigating on the question of a person's moral culpability if there were evidence the injury influenced that person's behavior. However, the appellant has failed to demonstrate the injuries he sustained in his motorcycle accident had any impact on his behavior the night of the murders, or that the members would have considered an unsupported proposition in that regard to have been sufficiently mitigating to render a more lenient sentence. We therefore conclude that the appellant was not prejudiced by his counsel's failure to introduce evidence of the accident and the appellant's injuries, because under the facts of this case we do not find a reasonable probability of a different outcome.⁴⁴⁴

C. Competence

Compared to the number of cases in the two previous categories, a relatively small number of appellate cases have been reported that implicate neuroimaging evidence with a defendant's competency to stand trial or change a plea.⁴⁴⁵ A possible reason for the small number of reported cases is

439. *Id.* at 759. A CT scan after the accident was normal, but an expert said it was too soon after the accident to be reliable for the defense's purposes. *Id.* at 766.

440. *Id.*

441. *Id.*

442. *United States v. Witt*, 73 M.J. 738, 753 (A.F. Ct. Crim. App. 2014) (en banc).

443. *Id.* at 783–84.

444. *Id.* at 776.

445. *See supra* Parts IV.A–B; Appendix C, *supra* note 2.

because competency is not a frequently raised issue on appeal. Thus, most cases in which neuroimaging evidence was introduced or discussed would not be detected using our methodology.⁴⁴⁶ However, of the 56 cases we identified that involved neuroimaging evidence relating to competency, 12 of them have occurred in the last few years, with three from 2013,⁴⁴⁷ five from 2014,⁴⁴⁸ and four from 2015.⁴⁴⁹ This data supports the contention that this type of evidence is being used with increased frequency, even at the competency stage of a trial, and is starting to be raised more frequently on appeal as well.

The competency cases include a few different types of claims: competency to stand trial, to enter a guilty plea, to be sentenced, or to be executed.⁴⁵⁰ In seven of those cases, the defendant had received a brain scan since the time of trial that was used to support his argument of lack of competency in some way.⁴⁵¹ In nine cases, the defendant had not had imaging performed but requested it in order to support his argument of lack of competency at the time of trial.⁴⁵² In 11 of 47 cases, the court granted a defendant's request for relief.⁴⁵³

The Supreme Court created the legal test for competency in *Dusky v. United States*, which set out a two-pronged test that requires a defendant to possess (1) "sufficient present ability to consult with [counsel] with a reasonable degree of rational understanding," and (2) "a rational as well as factual understanding of the proceedings"⁴⁵⁴ The competency requirement not only applies at the time of trial, but also at any time a defendant wishes to plead guilty to a charge or to waive counsel or appellate rights.⁴⁵⁵

Despite its constitutional importance, competency is a very narrow inquiry. It is narrow because a defendant must only be found competent during a small window of time—the exact time of the evaluation—and that

446. See *supra* Part III.

447. See Appendix C, *supra* note 2.

448. See *id.*

449. See *id.*

450. See *id.*

451. See *id.*

452. See *id.*

453. See *id.*

454. *Dusky v. United States*, 362 U.S. 402, 402 (1960) (per curiam).

455. *United States v. Hammer*, 404 F. Supp. 2d 676, 792–93 (M.D. Pa. 2005).

finding of competency carries forward throughout the defendant's prosecution.⁴⁵⁶ Following a conviction, evidence that a defendant proffers in support of his incompetence at the time of trial is reviewed in the same light as a motion for a new trial; the claim will only be granted if justice so requires.⁴⁵⁷ Timing is an important issue in a determination of competency because it is required that a defendant be competent before proceedings can begin against them or before they waive any of their constitutional rights.⁴⁵⁸ Consequently, retroactive competency hearings are not sufficient to satisfy the constitutional requirements set forth in *Dusky*.⁴⁵⁹

The defendant has the burden of proving incompetency,⁴⁶⁰ and this burden is even more difficult to carry at the appellate level than at trial. To disturb a prior finding of competency, a defendant first needs to present probative evidence that raises a substantial doubt of competency at the time of trial and then must prove incompetency by a preponderance of the evidence.⁴⁶¹ Unsubstantiated assertions of incompetency, by the defendant or an expert, do not constitute probative evidence.⁴⁶²

456. *See id.*

457. *See* FED. R. CRIM. P. 33(a).

458. *See Hammer*, 404 F. Supp. 2d at 792–93.

459. *United States v. Duncan*, 642 F.3d 1242, 1250 n.3 (9th Cir. 2011); *see McMurtrey v. Ryan*, 539 F.3d 1112, 1116, 1120–22, 1132 (9th Cir. 2008) (granting defendant's habeas petition on the ground that his due process rights were violated because a competency hearing held 13 years after trial could not render a meaningful determination of his competency; defendant's brain scans were normal, and in the expert's opinion, there was no evidence of neurological damage or disease).

460. *Hammer*, 404 F. Supp. 2d at 793.

461. *Vogt v. United States*, 88 F.3d 587, 591 (8th Cir. 1996); *Bruce v. Estelle*, 536 F.2d 1051, 1058–59 (5th Cir. 1976); *Hammer*, 404 F. Supp. 2d at 793–94 (rejecting IAC claim for failure to challenge defendant's competency when he changed his plea, discharged counsel, and later withdrew his appeal). In regards to the defense expert witness and PET scan evidence, the *Hammer* court stated: "Although we find [the expert] credible with respect to his psychological evaluation and neuroimaging of [the defendant], we do not find credible [the expert's] conclusion that [the defendant] was not competent and not acting voluntarily, intelligently and rationally at the time of (1) the change of plea proceeding, (2) the proceeding where he discharged counsel and was authorized to decide on his own whether to pursue an appeal and (3) the proceeding before the Court of Appeals when he withdrew his appeal." *Hammer*, 404 F. Supp. 2d at 719.

462. *Moody v. Johnson*, 139 F.3d 477, 481–82 (5th Cir. 1998) (denying defendant's claims for habeas corpus relief because he had no evidence he was incompetent at the time of trial; he merely made unsupported conclusions that he suffered from mental illness at the time of trial, including a claim that a CAT scan from 1984, the results of

When there is no evidence suggesting a defendant's incompetence, a trial court is not responsible for inquiring into a defendant's competence.⁴⁶³ Conversely, when there is evidence—because of defendant's behavior or suspicions by counsel—that raises doubt as to a defendant's competence, the trial court is required by law to convene a formal competency hearing.⁴⁶⁴ Requests for neuroimaging to support an argument of incompetency must be supported by a demonstration of particularized need—the same standard that must be met in guilt and mitigation.⁴⁶⁵ If a defendant has already undergone a psychiatric evaluation, requests for additional testing and brain scans to investigate further his alleged incompetency at the time of trial without specific justification can be labeled as a request for a fishing expedition and denied.⁴⁶⁶ When a defendant requests a brain scan or additional evaluations on appeal, he has the burden of showing the expert

which he did not provide to the court, revealed a likely brain aneurysm).

463. *Rainey v. Knowles*, No. C 07-00678 CW, 2008 WL 4104285, at *3–4 (N.D. Cal. Sept. 2, 2008) (rejecting defendant's argument on appeal that he had been incompetent to stand trial because neurological assessments and brain evidence revealed impairments and abnormalities, when nothing in the record raised any suspicion that a competency hearing had been required—defense counsel never doubted defendant's competency, to the contrary, defendant's statements regarding his defense suggested he was aware of and understood the proceedings against him), *aff'd* by 386 F. App'x 605 (9th Cir. 2010); *Taylor v. State*, 3 So. 3d 986, 997 (Fla. 2009) (*per curiam*) (finding no IAC for failure to demand a competency hearing or present evidence of defendant's mental health problems because there was never a question of defendant's competency, by defense counsel or mental health experts, thus, there was no cause that would require further investigation into defendant's competency or mental health).

464. *Tiller v. Esposito*, 911 F.2d 575, 576 (11th Cir. 1990) (citing *Pate v. Robinson*, 383 U.S. 375, 385 (1966)).

465. *See Hugueley v. Carpenter*, No. 09-1181-JDB-egb, 2015 WL 225053, at *15 (W.D. Tenn. Jan. 15, 2015); *see supra* Parts IV.A–B.

466. In *United States v. Phillips*, the defendant appealed his conviction of conspiracy to possess cocaine with the intent to distribute, arguing the trial court erred in denying his motion for a psychiatric evaluation and brain scan testing. *United States v. Phillips*, No. 89-5686, 1990 WL 92625, at *1 (6th Cir. July 3, 1990) (*per curiam*). The court rejected Phillips' claims as Phillips had already received a psychiatric evaluation, he was found competent to stand trial, and he failed to meet the burden of proof. *Id.* at *1–2. The court also noted that Phillips was merely trying to use the additional psychiatric evaluation and brain scan testing to go on a fishing expedition, which is exactly what is not allowed. *Id.* at *2; *see also* *Roach v. Martin*, 757 F.2d 1463, 1474 (4th Cir. 1985) (rejecting defendant's request for a PET scan to see if it could diagnose early Huntington's Disease (HD) as well as his argument that if he had the HD gene it could have affected his competency to stand trial and render his death sentence unconstitutional because the court found no way that if it was revealed the defendant had the HD gene how that would have affected the ruling he was sane at the time of the murders and competent to stand trial).

services requested are presently necessary or were necessary to his defense at trial.⁴⁶⁷

As difficult as competency is to litigate, there have been successful claims using neuroimaging evidence to show that a defendant was not competent to make a guilty plea,⁴⁶⁸ waive his right to counsel,⁴⁶⁹ be sentenced,⁴⁷⁰ or waive his right to appeal.⁴⁷¹ Recently, in the 2013 case of *United States v. Dreyer*, the Ninth Circuit agreed with defendant's contention that the lower court erred by not ordering a competency hearing.⁴⁷² In support of this claim, the defendant pointed to imaging evidence of "extensive frontal lobe damage" likely causing impairment in judgment.⁴⁷³ The court found there was enough evidence to create a reasonable doubt as to defendant's competency.⁴⁷⁴ The case was remanded for an evidentiary hearing.⁴⁷⁵

As the popularity of neuroimaging evidence continues to grow, it is likely that future defendants will seek to introduce neuroimaging evidence as early in a trial as possible, which would be the competency phase.⁴⁷⁶ And if the neuroimaging evidence is unsuccessful in helping a defendant establish lack of competence, then the evidence could still be valuable in the guilt and penalty phases.

V. DISCUSSION

From the cases included in this Article, some generalizations can be made about the impact neuroimaging evidence has actually had at the various stages of a trial. First, there has been a steady upward trend in the number of criminal cases considering neuroimaging evidence. Previous

467. *Phillips*, 1990 WL 92625, at *2.

468. *State v. Marshall*, 27 P.3d 192, 200 (Wash. 2001) (en banc), *abrogated by* *State v. Sisouranh*, 290 P.3d 942 (Wash. 2012) (en banc).

469. *Wilkins v. Delo*, 886 F. Supp. 1503, 1513 (W.D. Mo. 1995).

470. *United States v. Rothman*, No. 08-20895-CR, 2010 WL 3259927, at *35 (S.D. Fla. Aug. 18, 2010).

471. *See United States v. Duncan*, 643 F.3d 1242, 1249–50 (9th Cir. 2011) (remanding to district court for a hearing on competency).

472. *United States v. Dreyer*, 705 F.3d 951, 965 (9th Cir. 2013).

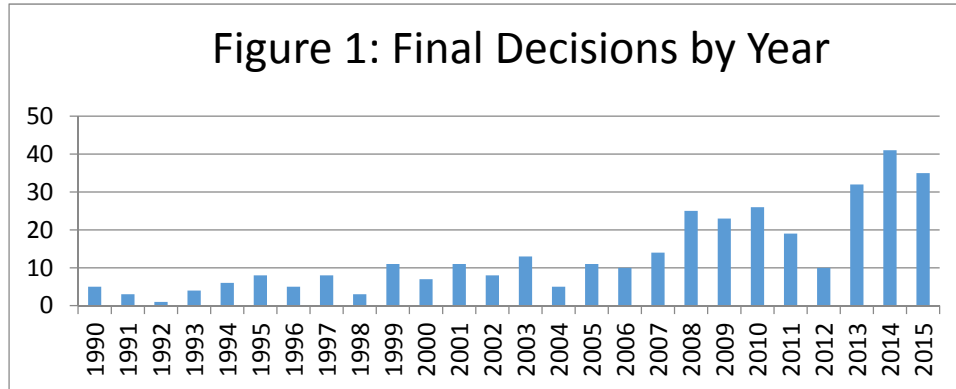
473. *Id.* at 958.

474. *Id.* at 962.

475. *Id.* at 965.

476. *See supra* notes 460–67 and accompanying text; *supra also* Appendix C, *supra* note 2.

empirical studies had reported an increase in neuroimaging cases through 2012,⁴⁷⁷ but the present study has observed an even steeper upwards curve in the subsequent period from 2012 through 2015.⁴⁷⁸ Indeed, as shown in Figure 1 below, the number of reported final decisions in criminal cases involving neuroimaging of the defendant have been highest in that subsequent period, 2013–2015.



Second (and not surprisingly given the caveats of the methodology of using reported cases where the defendant lost at trial and then appealed), in general, neuroimaging tests have not been successfully used to establish incompetency or to rebut guilt.⁴⁷⁹ Courts have been most receptive to and influenced by neuroimaging evidence during the penalty phase; for example, the Florida Supreme Court vacated a death sentence in favor of life without parole as a result of the mitigating evidence, particularly the evidence of brain damage and its relationship to the murder committed.⁴⁸⁰ One

477. See Denno, *supra* note 13; Faharney, *supra* note 16.

478. See *infra* Figure 1.

479. See *supra* note 2.

480. *Crook v. State*, 908 So. 2d 350, 353 (Fla. 2006) (per curiam); see *supra* notes 297–302 and accompanying text. The trial court found Crook’s death sentence disproportionate after a qualitative analysis of the aggravating and mitigating factors and concluding Crook’s case was one of the most mitigated. *Crook*, 908 So. 2d at 358–59. The evidence of Crook’s brain damage was a valid mitigating circumstance that had to be weighed in determining whether to sentence him to death. *Id.* at 359. Three defense experts presented uncontroverted testimony that the defendant suffered from frontal lobe brain damage; that testimony explained the causes and origins of the damage and established a causal link between the brain damage and the murder. *Id.* at 353, 359. The court cited a number of cases where the Florida Supreme Court had vacated death

overarching trend is obvious: more and more lawyers are making arguments on behalf of their clients involving brain damage demonstrated by neuroimaging, and consequently more courts are addressing the claims of brain damage or some aspect of brain function in their opinions.⁴⁸¹ Sometimes the topic warrants only a paragraph explaining why a particular claim is without merit and other times the topic covers multiple pages of discussion.⁴⁸² This is an area that judges and lawyers need to familiarize themselves with as its utilization in criminal trials is likely to increase. This area of law is especially relevant for defense lawyers who may face ineffective assistance of counsel claims for failing to adequately investigate mitigating mental health evidence, which includes the presence of brain

sentences for a life sentence as a result of mental health mitigating evidence: *Larkins v. State*, 739 So. 2d 90, 95–96 (Fla. 1999) (per curiam); *Hawk v. State*, 718 So. 2d 159, 162–64 (Fla. 1998) (per curiam), *abrogated by Connor v. State*, 803 So. 2d 598 (Fla. 2009) (per curiam); *Robertson v. State*, 699 So. 2d 1343, 1347 (Fla. 1997) (per curiam), *receded from by Delgado v. State*, 776 So. 2d 233 (Fla. 2000) (per curiam), *superseded by* FLA. STAT. § 810.015(1) (2002), *as recognized in Bradley v. State*, 33 So. 3d 664, 681 n.18 (Fla. 2010) (per curiam); *Morgan v. State*, 639 So. 2d 6, 14 (Fla. 1994) (per curiam); *Knowles v. State*, 632 So. 2d 62, 67–68 (Fla. 1993) (per curiam); *Nibert v. State*, 574 So. 2d 1059, 1063 (Fla. 1990); *Livingston v. State*, 565 So. 2d 1288, 1292 (Fla. 1988) (per curiam); *Miller v. State*, 373 So. 2d 882, 886 (Fla. 1979) (per curiam). The court does not require that brain damage be a mitigating factor in order for this disproportionality analysis to turn out in favor of the defendant. *See Crook*, 908 So. 2d at 358. Impaired capacity, diminished intellectual functioning, deprived childhood, severe childhood abuse, severe mental illness, young age at time of crime, and immaturity have all been listed, in some combination, with or without proof of brain damage, as mitigating evidence that is so substantial as to render the death penalty disproportionate. *See, e.g., id.* at 355–56, 358 (listing factors considered by trial court and compiling cases); *Nibert*, 574 So. 2d at 1062–63 (finding death sentence disproportionate in light of mitigating factors without evidence of brain damage). This indicates that while neuroimaging techniques to prove the existence of brain damage or dysfunction in a defendant can be useful, they are by no means necessary for the mental health mitigating evidence to rise to a level that warrants leniency and results in a reduced sentence for a capital crime.

481. *See supra* Figure 1.

482. *People v. Crittenden*, 885 P.2d 887, 932 (Cal. 1994) (en banc) (discussing brain-imaging mitigation evidence briefly); *Rogers v. State*, 783 So. 2d 980, 997–1000 (Fla. 2001) (per curiam). An example of a rather thorough discussion regarding PET scan evidence took place in the Florida Supreme Court's opinion in *Rogers*, 783 So. 2d at 997–1000. A four-page section of the opinion was devoted to appellant's claim that the trial court erred by denying his motion to have a PET scan. *Id.* The discussion included a review of claims contained in the defense expert's affidavit, the reason for the trial court's denial of the request, a survey of related case law where Florida defendants sought brain scans, and an explanation of why they found the appellant was not prejudiced by the denial of the scan. *Id.*

damage after the 2005 Supreme Court decision in *Rompilla*.⁴⁸³

Third, in recent years there has been somewhat of a shift from arguments about whether neuroimaging evidence is relevant and admissible in criminal defense cases to a focus on the substantive results of the neuroimaging. This trend is demonstrated by the recent phenomenon in which courts have increasingly relied on neuroimaging results showing no evidence of organic brain damage to reject defenses or mitigation claims by defendants.⁴⁸⁴

A. “New Chapter” in Death Penalty History

Because the presence of brain damage is becoming such a frequently raised issue in capital penalty cases, it is likely the use of neuroimaging data to help establish this damage is only going to increase. Another important point is that as this type of evidence becomes increasingly common, judges are beginning to disagree as to its significance and legal ramifications. In 2006, Judge Cole of the Sixth Circuit, joined by Judges Martin, Daughtrey, Moore, and Clay, wrote a dissenting opinion after the panel denied a petition for rehearing en banc that sought to overturn the death penalty sentence in the case of *Slaughter v. Parker*.⁴⁸⁵ In the first paragraph of the opinion, Judge Cole stated, “We are particularly troubled about executing someone who likely suffers brain damage. We rarely, if ever, allow that—especially when the jury is not afforded the opportunity to even consider that evidence.”⁴⁸⁶ Judge Cole and his colleagues believe that a “new chapter” has been reached in death penalty history and that the majority’s opinion and defendant Jeffrey Leonard’s pending execution cannot be reconciled with precedent.⁴⁸⁷ Particularly troubling to these judges was that evidence of Leonard’s possible brain damage—“from an untreated childhood skull fracture near

483. See *supra* Part IV.B.4.

484. See *supra* notes 228, 329 and accompanying text.

485. *Slaughter v. Parker*, 467 F.3d 511, 512 (6th Cir. 2006) (Cole, J., dissenting).

486. *Id.*

487. *Id.*; see, e.g., *Harries v. Bell*, 417 F.3d 631, 639–40, 642 (6th Cir. 2005) (granting relief where defendant had damage in the frontal lobe of his brain, which “can interfere with a person’s judgment and decrease a person’s ability to control impulses”); *Hamblin v. Mitchell*, 354 F.3d 482, 490, 493–94 (6th Cir. 2003) (granting relief where jury did not hear of defendant’s brain damage attributed to a severe blow to the head during childhood); *Glenn v. Tate*, 71 F.3d 1204, 1207, 1211 (6th Cir. 1995) (granting relief where jury did not hear of defendant’s brain damage).

his right frontal lobe”—was never presented to the jury.⁴⁸⁸ Nor was the jury presented with testimony from Leonard’s younger siblings because they were unaware that he was on trial, since he was prosecuted under the alias James Slaughter.⁴⁸⁹ The judges were not certain that a jury would have sentenced Jeffrey Leonard, “a likely brain-damaged man whose family would corroborate his testimony and plead for his life,” to death had they been presented this additional evidence, but they recognized they would never know, due to the majority’s decision to deny a rehearing.⁴⁹⁰ The neuroimaging data of Jeffery Leonard and expert testimony regarding his neurological and mental status, and how those could be related to any imaging findings, would have been appropriate in the penalty phase of his trial. Such evidence could have satisfied part of the judges’ unease because as far as the brain damage was concerned, the jury was not presented with a complete picture.

B. *Fears and Concerns*

Commentators on the law of neuroscience have correctly pointed out that it is extremely difficult to link a brain scan to criminal behavior and violence.⁴⁹¹ Crime is a social construct and violence an incredibly complicated behavior. Suggesting that the reason neuroimaging data is being collected in relation to criminal cases is to look for a way to explain criminal or violent behavior, solely with findings on a scan, is a gross oversimplification of a complex issue. Rather, what experts may reasonably try to do is to link the neuroimaging findings, if any, to a construct or condition (such as neurodevelopmental disorders, traumatic brain injury, etc.).⁴⁹² It is that construct or condition that then has implications, some of which may be legally relevant—meaning they may speak to some of the factors or criteria addressed in a legal standard.⁴⁹³ Defendants charged with capital murder present histories that usually include some or all of the following with varying degrees of severity: toxic exposure (e.g., fetal

488. See *Slaughter*, 467 F.3d at 512.

489. *Id.*

490. *Id.* at 514.

491. See, e.g., Compton, *supra* note 1, at 342.

492. See, e.g., Ward v. Barnes, No. CV 09-8917-JGB(JC), 2014 WL 1716065, at *4 (C.D. Cal. Apr. 2, 2014), *report and recommendation adopted*, No. CV 09-8917 JGB(JC), 2014 WL 1716068 (C.D. Cal. Apr. 28, 2014).

493. See *supra* Part II.B.

alcohol), abuse, a history of head injuries, mental health issues, and alcohol and substance abuse.⁴⁹⁴ By suggesting that the purpose of the imaging is to look for a link to violence, commentators either ignore or forget the vast majority of the neurological, mental health, and developmental conditions for which neuroimaging can provide important information.⁴⁹⁵ And unfortunately, the presence of some of those conditions may be risk factors for the perpetration of violence.

The fear that neuroimaging techniques are going to lead judges and jurors to place an inordinate amount of weight on these techniques and be swept away by the power of the visual image remains unrealized.⁴⁹⁶ It is important to keep in mind that most criminal defendants who use neuroimaging tests and testimony are not going to be set free once they establish they have some sort of neurological dysfunction or damage—they are still going to be subject to some level of state sanction.⁴⁹⁷ For example, in a capital case, if persuaded by the neuroimaging evidence that a defendant is deserving of some leniency, the jury could vote for life without parole instead of the death penalty. In a competency hearing, if used successfully, neuroimaging evidence could support a determination that a defendant is incompetent to stand trial, in which case the defendant would be sent to a facility for treatment and further evaluation and, within a certain number of days he or she would come before the court again to have competency reevaluated. The biggest impact the evidence could have is obviously in the guilt phase, but rather than seeking to use brain scans to totally absolve a defendant of responsibility for the crime charged—which is extremely rare and limited to “pedophilic tumor” type of cases—the neuroimaging evidence has typically been used to rebut intent or premeditation, merely changing the severity of the murder charge, not dismissing it altogether.⁴⁹⁸ The case law suggests that rather than defendants making the claim “I have an abnormal brain scan, I should not be held responsible for my actions in any way,” scans are being used to support much more modest claims—merely

494. See generally cases cited in Appendices A, B, & C, *supra* note 2.

495. See *supra* Parts II.A–B.

496. E.g., Schweitzer et al., *supra* note 68.

497. See, e.g., *Harries v. Bell*, 417 F.3d 631, 642 (6th Cir. 2005) (affirming decision denying defendant’s writ regarding his guilt, but affirming decision to vacate death penalty). See generally Appendices B & C, *supra* note 2.

498. See *supra* Part IV.A.1.a.

softening the blow that the criminal justice system is going to give the defendant by convicting him or her of a lesser crime or handing down a more lenient sentence.⁴⁹⁹

For now, it appears the timeless debates of free will, determinism, and responsibility should remain in philosophy and criminal law classrooms. The criminal justice system seems adequately equipped to deal with neuroimaging evidence. Over time, precedent will continue to develop and more detailed legal tests will evolve to address this particular type of evidence in the various contexts it is presented. Attorneys seeking to obtain and use this type of evidence in their cases have responsibilities to learn what types of neuroimaging evaluations are appropriate under what circumstances, discern how the data relates to various mental health conditions and constructs, and present the court with complete, detailed information relating to the relevance and importance of this data, effectively illustrating how it helps them and their experts fully evaluate and, therefore, better understand their client. This process is already underway and judges are evaluating neuroimaging evidence with patience and skill—a number of majority and dissenting opinions reflecting an excellent understanding of neuroimaging evidence and testimony and many judges appearing to recognize its legal utility and limitations.

C. The Future of Neuroimaging Evidence in the Courtroom

The million dollar question—or perhaps \$300 million question (as that is the value of President Obama’s Brain Initiative)⁵⁰⁰—is what is the link between the brain and behavior? More precisely, the legal system wants to know what the causal relationship is between brain damage or dysfunction as reflected by neuroimaging procedures and subsequent criminal or violent behavior.⁵⁰¹ Neuroscience and neuroimaging techniques have not revealed a direct causal mechanism for extremely complex behaviors like violence, but they help us better understand brain structure and function in varying states of health and disease and are associated with varying disorders.⁵⁰² As with so many other forms of evidence, the relationship between neuroimaging-

499. See *supra* Part IV.A.1.a.

500. *BRAIN Initiative*, WHITE HOUSE (Sept. 30, 2014), <https://www.whitehouse.gov/share/brain-initiative>.

501. See *supra* Part II.B.

502. See *supra* Part II.B.

based evidence and the legal issue at hand is most often one of probabilities.⁵⁰³ It is interesting that the law, which bases its decisions on probabilities, expects more from other disciplines—particularly science.⁵⁰⁴ It wants science to be clear-cut, answering any question with a definitive yes or no. While the determinations the law makes are black and white—guilty versus not guilty—it gets to its decisions as a result of probabilities, not certainties. While the high (perhaps unrealistic) expectations the law places on science do not excuse experts grossly exaggerating the relationship between brain damage and behavior, neither do they mean that brain-based evidence is not fit for the courts. If the appropriate data was collected, that data was analyzed properly, and the corresponding expert testimony is accurate in strength and scope, it can provide a valuable check for many psychological and psychiatric diagnoses and provide supplementary evidence to support expert testimony, helping the fact-finder arrive at a more informed conclusion about a defendant's neurological status and mental health.⁵⁰⁵

From a defense perspective, neuroimaging evidence is merely another piece of evidence that can help illuminate the defendant's mental state for mitigation purposes and potentially around the time of the crime. But this overly "simplistic" view has been criticized by neuroscientists and researchers.⁵⁰⁶ Criticisms of brain scans as legal evidence include, but are not limited to: false positives, individual variability in brain structure making true identification of abnormalities difficult, and the causation issue (even if an abnormality is identified, what connection, if any, does it have to specific behaviors).⁵⁰⁷ All of these concerns are reasons that behavioral evidence is still—and will likely always be—necessary evidence when it comes to establishing various mental health conditions.⁵⁰⁸ Particularly in the context

503. See *supra* Part II.B.

504. See *supra* Part II.B.

505. See *Rogers v. State*, 783 So. 2d 980, 998 (Fla. 2001) (per curiam).

506. See Michael S. Gazzaniga & Megan S. Steven, *Neuroscience and the Law*, SCI. AM. MIND, Apr. 2005, at 42, 49; Scott T. Grafton et al., *Brain Scans Go Legal*, SCI. AM. MIND, Dec. 2006, at 30, 33–34.

507. See *supra* Part II.B.

508. See, e.g., *Owen v. State*, 986 So. 2d 534, 553 (Fla. 2008) (per curiam) (explaining the facts of defendant's calculated murder of the victim "largely refuted the theory that [the defendant] acted impulsively at the time of the crime"); see *supra* Part IV.

of murder, when the defendant attempts to use neuroimaging evidence to support the claim that the defendant was incapable of premeditation or forming intent, courts look at the circumstances of the murder and the defendant's behavior surrounding the crime to rebut those arguments; it is often concluded that the defendant's behavior belies the claim that the defendant did not or could not know what he or she was doing.⁵⁰⁹ And despite worries that jurors will be overwhelmed by the power of the visual when presented with brain scan images, to the contrary, in many capital cases, jurors seem to give much more credence to the victim and the crime committed than to neuroimaging evidence, leading them to convict and recommend the death sentence.⁵¹⁰

According to Grafton et al., “[t]he best an expert witness in a courtroom [can] do is establish a weak correlation between brain injury and criminal behavior.”⁵¹¹ Many experts that testify in criminal trials explain the utility and acknowledge the limitations of neuroimaging results,⁵¹² while other experts make much stronger claims.⁵¹³ The potential role of neuroimaging evidence should not be understated or overstated. Neuroimaging evidence by itself—like virtually every other type of evidence—is rarely, if ever, determinative of any of the ultimate legal issues relating to guilt, responsibility, and culpability, but if used properly, it can contribute to the difficult chore of trying to resolve such questions with inevitably incomplete and imperfect evidence. To have utility in the courtroom, evidence does not need to be dispositive of an issue in a case or of the entire case itself. If that were the standard, not much could be admitted into evidence. Neuroimaging evidence is relevant to many aspects of the human condition, which is why it already has been and will continue

509. See, e.g., *Ex Parte Jennings*, Nos. AP-75806, AP-75807, 2008 WL 5049911, at *3, *7 (Tex. Crim. App. Nov. 26, 2008) (finding the facts of the crime undermined any evidence that the crime was committed impulsively or without thought on part of the defendant); see *supra* Part IV.A.

510. See *supra* Part IV.B.1.

511. Grafton et al., *supra* note 506, at 34.

512. See *People v. Holt*, 937 P.2d 213, 231 (Cal. 1997) (concluding PET and EEG testing revealed damage to both left and right temporal lobes, which resulted in abnormal brain function, but that the data collected from the brain scans could not be used to predict violent behavior).

513. See *People v. Morgan*, 719 N.E.2d 681, 693 (Ill. 1999) (concluding that at the time of the offense the defendant's aggressive and violent behavior was the direct result of brain damage).

to be involved in so many cases.

D. A Final Thought Experiment

Even the diagnosis of a neurological condition in a defendant does not rule out the possibility that it was not the neurological condition that caused the behavior at a given time. Unless a diagnosis can be said to have 100 percent causal relationship to the behavior in question and rule out every other cause, a gap is left where a particular defendant may fall, meaning the determination that the defendant was or was not responsible for his or her action is still a guess—an educated guess—but still a guess. An example is an individual with Coprolalia, the neuropsychiatric disorder that causes those inflicted spontaneously to use profane and obscene language and is often mistaken for Tourette's syndrome.⁵¹⁴ If an individual inflicted with Coprolalia is walking down a street and passes a playground full of young children while shouting obscenities, the police may be called and that individual arrested. However, he would have a potential excuse for his behavior, that is, his disorder “made him do it”: he physically could not help speaking the obscene words because of his condition, and we might accept that as a valid justification or excuse.⁵¹⁵ Yet, there is also the chance that his Coprolalia did not make him do it; he was not suffering from an episode at that time, and he was simply very angry and cursing voluntarily. But when threatened with punishment, his disorder provided a convenient excuse. In that case, the individual was culpable and acted rationally when he chose to swear. But how would the truth be known? Would evidence of his neurological disorder be blindly accepted without investigation? Perhaps yes, perhaps no. But it is precisely this gray area presented by this hypothetical that the criminal justice system was designed to address: an evaluation of human behavior that is outside of acceptable social norms, to determine whether such behavior warrants sanction. All the imaging data in the world cannot answer the question of whether what an individual did at a certain time and place is deserving of some sort of punishment. Science cannot answer questions of legal responsibility, just as the law cannot answer questions of science. However, even if it does not completely explain or

514. Natalie Wolchover, *Why Does Tourette's Make People Curse Uncontrollably?*, LIVE SCI. (July 8, 2011), <http://www.livescience.com/33384-tourette-syndrome-people-curse-uncontrollably.html>.

515. Hank T. Greely, *Neuroscience and Criminal Responsibility: Proving “Can't Help Himself” as a Narrow Bar to Criminal Liability*, in 13 LAW AND NEUROSCIENCE, CURRENT LEGAL ISSUES (Michael Freeman ed., 2010).

excuse the criminal behavior in question, neuroimaging data, when used appropriately, can help make evaluations and decisions more informed, fair, and evidence-based.

VI. CONCLUSION

This Article has surveyed 361 U.S. criminal cases involving the use or attempted use of neuroimaging evidence in nine different contexts: four relating to the guilt phase, four relating to the penalty phase, and one relating to competency. This empirical assessment shows a general trend toward more sophisticated and nuanced arguments and applications of neuroimaging evidence in criminal law cases. Neuroimaging evidence alone will likely not answer any of the central questions in a criminal law case, but when introduced with sufficient explanation and combined with other types of evidence, neuroimaging evidence can contribute to a more informed, fair, and evidence-based application of criminal punishment.